

Glandular Tumors of the Urachus and Urinary Bladder

A Practical Overview of a Broad Differential Diagnosis

Alexander S. Taylor, MD; Rohit Mehra, MD; Aaron M. Udager, MD, PhD

• **Primary glandular tumors of the urachus and urinary bladder are an intriguing group of clinically and morphologically diverse neoplasms for which there have been recent refinements in diagnostic subclassification and advances in molecular pathology. In addition, the urachus and urinary bladder may be secondarily involved by tumors with glandular differentiation that demonstrate remarkable morphologic, immunophenotypic, and molecular overlap. Thus, surgical pathologists need to be aware of the broad differential diagnosis of glandular tumors that involve the urachus and urinary bladder and have a practical diagnostic framework to evaluate these lesions in routine clinical practice. In this review, we summarize the salient clinical, morphologic, immunohistochemical, and molecular features of glandular tumors of the urachus and urinary bladder, including mucinous cystic tumors of the urachus, noncystic urachal adenocarcinomas, urothelial carcinomas with glandular or pseudoglandular features, primary urinary bladder adenocarcinomas, and Müllerian-type carcinomas, highlighting the strengths and limitations of various diagnostic features and ancillary tests, as well as the need for close clinical and radiographic correlation.**

(*Arch Pathol Lab Med.* 2018;142:1164–1176; doi: 10.5858/arpa.2018-0206-RA)

The differential diagnosis of glandular tumors of the urachus and urinary bladder is broad and includes both primary tumors and those demonstrating secondary involvement via either direct extension or metastasis (Table 1). These entities—both common and uncommon—can demonstrate remarkable morphologic similarity, and surgical pathologists must be aware of the full gamut of possible lesions to avoid misdiagnosis. Moreover, there are important prognostic and therapeutic implications to accurate

diagnosis, as the knowledge base surrounding the natural histories and molecular drivers of these neoplasms continues to grow. In this review, we provide a practical framework for approaching the diagnosis of glandular tumors of the urachus and urinary bladder, highlighting the strengths and limitations of various diagnostic features and ancillary tests.

GLANDULAR URACHAL TUMORS

The urachus is a vestigial fibrous remnant of the allantois, the canal that drains urine from the developing fetus.¹ While the allantois begins to gradually involute during fetal development, incomplete obliteration can result in a tubular or cystic urachal remnant observed in approximately one-third of adults at the time of autopsy.² Urachal remnants are composed of urothelium, submucosal connective tissue, and smooth muscle¹; this urothelial lining may undergo focal glandular metaplasia, and urachal remnants may be a source of malignancy—accounting for less than 1% of bladder carcinomas³ but up to 10% of bladder adenocarcinomas.⁴ As initially proposed by Sheldon et al³ and Mostofi et al⁵ and subsequently modified by Gopalan et al,⁶ the definition of a primary glandular urachal tumor includes (1) location of the tumor in the dome and/or anterior wall of the urinary bladder; (2) epicenter of the tumor in the urinary bladder wall; (3) absence of widespread cystitis cystica/glandularis beyond the dome and/or anterior wall of the urinary bladder; and (4) absence of a known primary elsewhere. While the presence of an associated urachal remnant supports the diagnosis of a primary glandular urachal tumor, the absence of a urachal remnant does not exclude this possibility. From a nosologic standpoint, most clinicopathologic studies of primary glandular urachal tumors have focused on histologic subtyping of the epithelial component (ie, enteric, mucinous)^{3,5–13}; however, a classification system recently proposed by Amin et al¹⁴ delineates primary glandular tumors of the urachus into 2 broad categories based on overall architecture: mucinous cystic tumors and noncystic adenocarcinomas. Although the field is gravitating toward acceptance of this practical and clinically useful classification system, in the future, there may be need for further refinement based on integration of clinicopathologic findings and molecular features of these enigmatic and poorly understood neoplasms.

Mucinous Cystic Tumors

Although the exact incidence has not been reported in a large contemporary cohort of consecutive tumors, mucinous

Accepted for publication May 2, 2018.

From the Department of Pathology, University of Michigan Medical School, Ann Arbor (Drs Taylor, Mehra, and Udager); Rogel Cancer Center, Michigan Medicine, Ann Arbor (Dr Mehra); and Michigan Center for Translational Pathology, Ann Arbor (Dr Mehra).

The authors have no relevant financial interest in the products or companies described in this article.

Presented in part at the New Frontiers in Pathology meeting; University of Michigan; October 19–21, 2017; Ann Arbor, Michigan.

Corresponding author: Aaron M. Udager, MD, PhD, Department of Pathology, University of Michigan Medical School, 2G332 UH, 1500 E Medical Center Dr, Ann Arbor, MI 48109-5054 (email: udager@umich.edu).

Table 1. Diagnostic Framework for Classification of Glandular Tumors of the Urachus and Urinary Bladder

| |
|--|
| Urachal tumors |
| Mucinous cystic tumors |
| Mucinous cystadenoma |
| Mucinous cystic tumor of low malignant potential with or without intraepithelial carcinoma |
| Mucinous cystadenocarcinoma with microscopic or frank invasion |
| Noncystic adenocarcinoma |
| Enteric-type |
| Mucinous |
| Not otherwise specified |
| Urinary bladder tumors |
| Urothelial carcinoma |
| Glandular features |
| Micropapillary features |
| Nested/microcystic features |
| Plasmacytoid/signet ring/diffuse growth pattern |
| Lipid-rich (lipoid) features |
| Adenocarcinoma |
| Enteric-type |
| Mucinous |
| Not otherwise specified |
| Müllerian-type carcinoma |
| Clear cell |
| Endometrioid |
| Villous adenoma |
| Secondary involvement of the urachus or urinary bladder (ie, direct extension or metastasis) |
| Colorectal adenocarcinoma |
| Prostatic adenocarcinoma |
| Acinar |
| Ductal |
| Metastases from other primary sites (ie, breast, stomach, gynecologic tract) |

cystic tumors likely represent a small subset of primary glandular neoplasms of the urachus. These tumors demonstrate an interesting morphologic homology with mucinous tumors of the ovary, a fact that is reflected by the diagnostic entities proposed by Amin et al¹⁴: (1) mucinous cystadenoma; (2) mucinous cystic tumor of low malignant potential (MCTLMP), with or without intraepithelial carcinoma (IEC); and (3) mucinous cystadenocarcinoma with either microinvasion or frank invasion. Grossly, mucinous cystic tumors will have a predominantly cystic appearance with abundant intraluminal mucin. Mucinous cystadenoma is an uncommon tumor of the urachus, probably representing less than 10% to 20% of all mucinous cystic tumors; it is a simple cystic tumor lined by a single layer of bland-appearing mucinous columnar epithelium with minimal cytologic atypia and architectural complexity (Figure 1, A and B). Mucinous cystic tumor of low malignant potential is the most common mucinous cystic tumor of the urachus, constituting more than 50% of such tumors. In contrast to mucinous cystadenoma, MCTLMP is composed of an architecturally complex glandular epithelial proliferation with mild to moderate atypia (Figure 1, C and D). For this reason, MCTLMP has been thought of as morphologically

analogous to atypical proliferative mucinous (borderline) tumor of the ovary. In addition, the appearance and degree of cytologic atypia in MCTLMP often resembles that seen in villous adenomas of the lower gastrointestinal tract (or urinary bladder; see below), including nuclear elongation and pseudostratification (Figure 1, D), and for this reason, MCTLMP may pose a diagnostic challenge for a variety of well-differentiated glandular tumors of the urachus and urinary bladder (see below). In a small subset of cases, MCTLMP may harbor foci of IEC, composed of tumor with prominent cribriform architecture, conspicuous cytologic atypia, and increased mitotic activity (Figure 1, E and F)—although, by definition, no stromal invasion should be present. Finally, mucinous cystadenocarcinoma is an uncommon tumor of the urachus, probably representing 10% to 20% of all mucinous cystic tumors. Although it may show significant morphologic overlap with MCTLMP, mucinous cystadenocarcinoma should demonstrate (1) unequivocal destructive infiltrative growth into the surrounding perivesical adipose tissue; and/or (2) microscopic foci of marked atypical and irregular glandular epithelial cells within the subjacent stroma with associated desmoplastic response (Figure 1, G and H). For mucinous cystadenocarcinoma of the urachus, Amin et al¹⁴ proposed a cutoff of 2 mm (and less than 5% of overall tumor volume) for distinguishing between microinvasion and frank invasion, although the reproducibility and clinical significance of this distinction have not been evaluated. Importantly, mucinous cystic tumors of the urachus frequently show adjacent reactive stromal changes, including fibrosis, hyalinization, chronic inflammation, and dystrophic calcification, which can entrap the overlying epithelium (ie, “pseudoinvasion”) and lead to an overdiagnosis of invasive mucinous cystadenocarcinoma.

Noncystic Adenocarcinomas

Noncystic adenocarcinomas are thought to constitute the vast majority of primary glandular neoplasms of the urachus. In contrast to mucinous cystic tumors, noncystic adenocarcinomas have a solid gross appearance and are typically frankly invasive.¹⁴ Morphologically, noncystic adenocarcinomas of the urachus are similar to primary adenocarcinomas of the urinary bladder and can demonstrate a range of histologic subtypes including (1) enteric-type adenocarcinoma; (2) mucinous adenocarcinoma, with or without signet ring cells; and (3) adenocarcinoma, not otherwise specified (see below for additional details).

Immunohistochemistry

The immunohistochemical profile of noncystic urachal adenocarcinomas is essentially identical to that of mucinous cystic tumors, with both groups typically demonstrating variable cytokeratin (CK) 7 and diffuse CK20 and CDX2 expression^{6,14,15}; these tumors are also usually negative for p63 expression. Unfortunately, this immunophenotype is relatively nonspecific and precisely overlaps with several of its main differential diagnoses, including primary urinary bladder adenocarcinoma and colorectal adenocarcinoma (Table 2). While diffuse nuclear β -catenin accumulation is frequently observed in colorectal adenocarcinomas (typically corresponding to APC mutations and corresponding Wnt pathway activation), patchy nuclear β -catenin accumulation may be present in a small subset of primary glandular urachal tumors, which potentially limits its value in routine clinical practice.^{6,15} Regardless, in the appropriate clinical context, membranous β -catenin expression is consistent

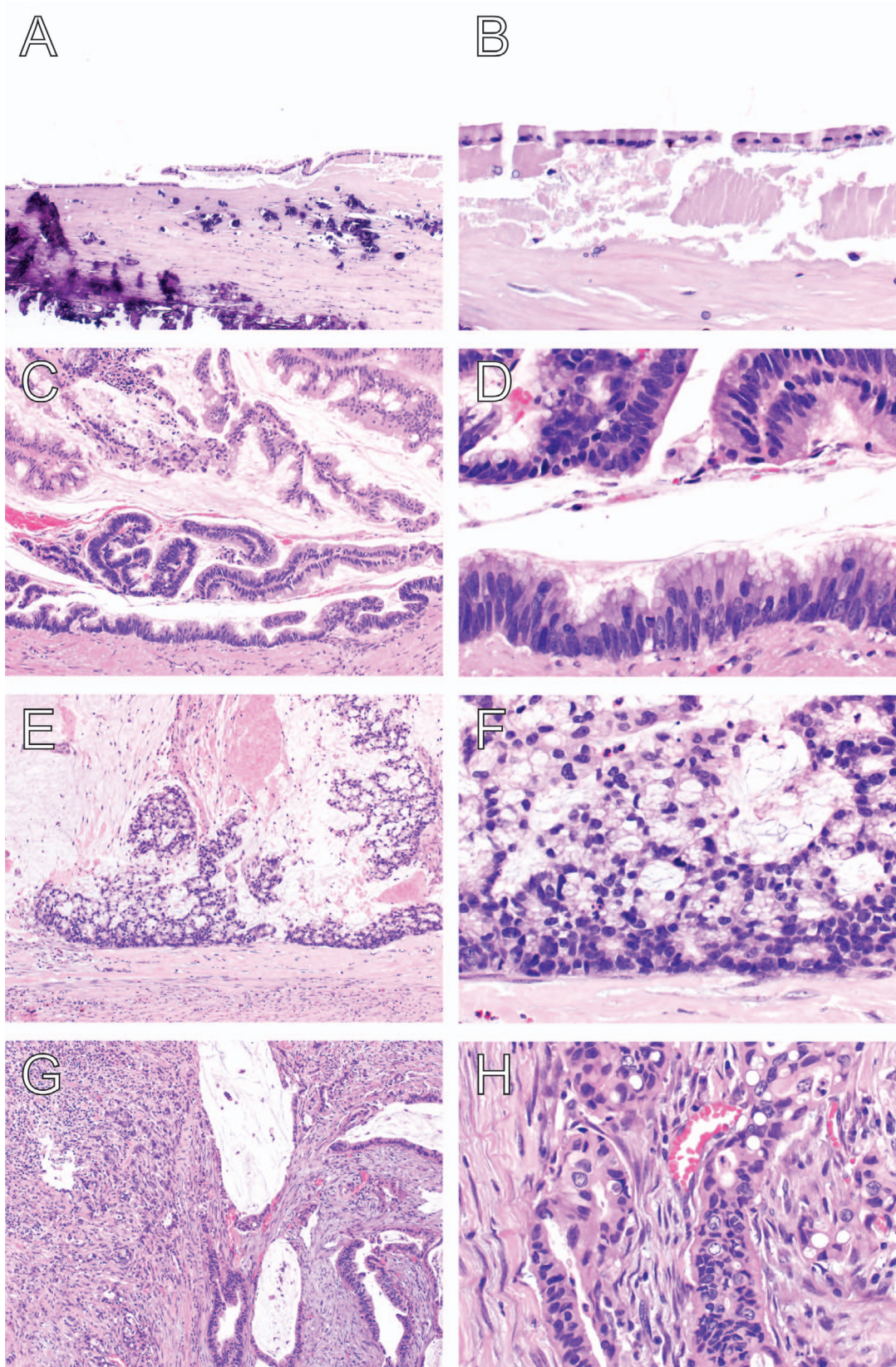


Figure 1. Mucinous cystic tumors of the urachus. Hematoxylin-eosin images showing the morphologic spectrum of primary mucinous cystic tumors of the urachus, including (A, B) mucinous cystadenoma; (C, D) mucinous cystic tumor of low malignant potential (MCTLMP); (E, F) intraepithelial carcinoma (IEC); and (G, H) invasive cystadenocarcinoma. Grossly, all tumors will have a predominantly cystic appearance with abundant intraluminal mucin (not shown). Microscopically, mucinous cystadenoma is architecturally simple and lined by bland-appearing glandular mucinous epithelium; the subjacent stroma may show prominent hyalinization and/or dystrophic calcification. MCTLMP is a noninvasive tumor composed of

Table 2. Key Immunohistochemical Patterns of Glandular Tumors of the Urachus and Urinary Bladder

| Tumor | CK7 | CK20 | p63 | GATA3 | CDX2 | PAX8 | NKX3-1 | β-Catenin |
|-----------------------------------|-----|------|-----|-------|------|------|--------|------------|
| Urachal neoplasm | +/- | + | - | Unk | + | Unk | Unk | Mem |
| Conventional urothelial carcinoma | + | +/- | + | + | - | - | - | Mem |
| Primary adenocarcinoma | +/- | + | - | - | + | - | Unk | Mem |
| Müllerian-type carcinoma | + | - | - | Unk | Unk | + | Unk | Unk |
| Colorectal adenocarcinoma | +/- | + | - | - | + | - | - | Mem or Nuc |
| Prostatic adenocarcinoma | - | - | - | - | - | - | + | Mem |

Abbreviations: CK, cytokeratin; Mem, membranous staining; Nuc, nuclear accumulation; Unk, unknown, presumably negative or membranous (β-catenin); +, positive; +/-, variable; -, negative.

with a primary urachal neoplasm. Finally, while not extensively studied in the context of the proposed diagnostic classification by Amin et al,¹⁴ claudin-18 appears to be expressed in a significant proportion of noncystic urachal adenocarcinomas but not mucinous cystic tumors¹⁵; however, additional data are needed to support the potential utility of claudin-18 in this specific differential diagnosis.

Prognosis and Staging

The classification scheme proposed by Amin et al¹⁴ is further justified by their observation of distinct prognostic differences between the 2 main tumor groups. In general, urachal mucinous cystic tumors confer a very good overall prognosis. Indeed, in the subset of cases with clinical follow-up, no patients with mucinous cystic tumors of the urachus experienced recurrence or metastasis after complete excision; this group included cases of MCTLMP with IEC and mucinous cystadenocarcinoma with microinvasion.¹⁴ In contrast, noncystic urachal adenocarcinomas often present as high-stage disease and typically have a very poor overall prognosis, with frequent metastatic spread and lethal progression. Since MCTLMP and mucinous cystadenocarcinoma may show morphologic overlap with noncystic urachal adenocarcinoma, this observed prognostic dichotomy necessitates care to avoid diagnostic misclassification. In all cases of glandular tumors of the urachus, correlation of the gross tumor architecture (ie, cystic versus solid) with the microscopic morphologic features is key to accurate diagnosis.

In addition to diagnostic classification, staging of urachal neoplasms yields important prognostic information. The Sheldon system is the most commonly used staging system for urachal neoplasms, with potential clinical utility demonstrated in several studies^{6,7,13,16,17}; it incorporates pathologic and clinical information to divide tumors as follows: localized to the urachal mucosa (pT1); extending into the urachal muscular layer (pT2); locally extending into the urinary bladder, abdominal wall, or other adjacent organs (pT3); and metastatic tumors (pT4).³ Interestingly, application of the Sheldon system to the classification scheme proposed by Amin et al¹⁴ would, by definition, make the vast majority of mucinous cystic tumors low-stage (even when invasive), while most noncystic adenocarcinoma would be high-stage; thus, it is unclear whether histology or stage is truly driving clinical prognosis in these cases. Regardless, a variety of other similar staging systems have

been proposed for urachal tumors (including Mayo [pathologic and clinical], Ontario [pathologic], and American Joint Committee on Cancer [AJCC] TNM [pathologic and clinical; adapted from the urinary bladder system]), and in general, retrospective analyses across staging systems have shown consistent findings across a variety of independent cohorts: clinically localized tumors have a good overall prognosis, while locally advanced and/or metastatic tumors have a poor overall prognosis.^{6,7,13,16-18} Based on this observation, and coupled with the practical challenge of determining the extent of invasion within the urachus for otherwise clinically localized tumors, there is current interest in a simplified dichotomous approach to staging primary urachal neoplasms: (1) tumors that are confined to the urachus, bladder, and perivesicular tissues and can be surgically excised; and (2) tumors that have intraperitoneal spread of disease¹⁶; however, additional validation of and consensus for this dichotomized urachal staging system is needed before widespread clinical implementation.

Molecular Pathology

Finally, recent next-generation sequencing of primary urachal tumors has begun to elucidate the molecular underpinnings of these uncommon neoplasms. Interestingly, the spectrum of molecular alterations in urachal tumors is distinctly different from that of conventional urothelial carcinoma and, instead, is more similar to primary urinary bladder adenocarcinoma and colorectal adenocarcinoma. Primary urachal tumors harbor recurrent *KRAS*, *NRAS*, *BRAF*, *APC*, *TP53*, *NF1*, and/or *SMAD4* mutations but generally lack *TERT* promoter and *PIK3CA* mutations,¹⁹⁻²⁴ which are common in conventional urothelial carcinoma (see below); in addition, focal *FGFR* gene family (*FGFR1*, *FGFR2*, and *FGFR3*) and/or *EGFR* amplifications have been reported in subsets of primary urachal tumors.²³ Importantly, most of the sequencing studies to date have not explicitly subclassified urachal tumors according to the system proposed by Amin et al,¹⁴ and thus, it remains unclear whether there are molecular differences between mucinous cystic tumors and noncystic adenocarcinomas of the urachus.

PRIMARY URINARY BLADDER TUMORS WITH GLANDULAR OR PSEUDOGLANDULAR FEATURES

Primary urinary bladder tumors frequently demonstrate glandular or pseudoglandular features. While histologic

←
architecturally complex glandular mucinous epithelium with mild to moderate cytologic atypia, including elongated oval nuclei with pseudostratification; IEC is a noninvasive tumor that frequently shows prominent cribriform architecture, conspicuous cytologic atypia, and increased mitotic and/or apoptotic activity. Invasive cystadenocarcinoma is an invasive tumor composed of infiltrating irregular nests of atypical glandular epithelium with marked cytologic atypia, conspicuous mitotic activity, and stromal desmoplasia (original magnifications ×10 [A, C, E, and G] and ×40 [B, D, F, and H]).

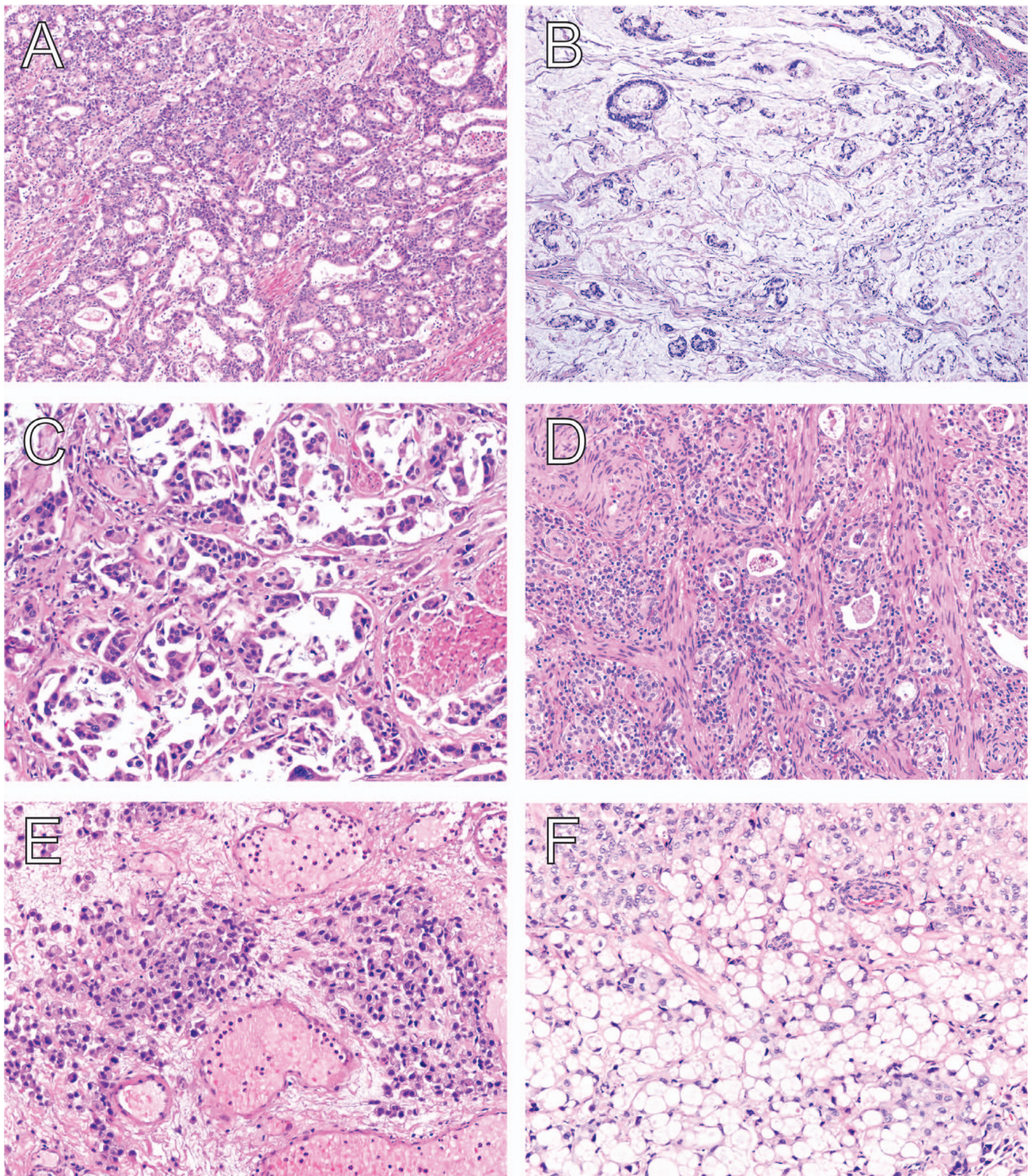


Figure 2. Urothelial carcinoma with glandular or pseudoglandular features. Hematoxylin-eosin images showing the morphologic spectrum of glandular or pseudoglandular features in urothelial carcinoma, including (A, B) glandular features; (C) micropapillary features; (D) nested/microcystic features; (E) plasmacytoid features; and (F) lipid-rich (lipoid) variant. Histologic subtypes of urothelial carcinoma with glandular features include (A) enteric and (B) mucinous types, which are morphologically indistinguishable from the enteric and mucinous types of primary noncystic urachal adenocarcinoma and primary urinary bladder adenocarcinoma (eg, compare Figures 2, B, and 3, B). Urothelial carcinoma with micropapillary features is morphologically similar to breast and lung carcinomas with micropapillary features; it is typically composed of tumor cells with moderate vacuolated cytoplasm, arranged in multiple small clusters (representing pseudopapillary structures without true fibrovascular cores) within variably sized lacunae. Urothelial carcinoma with nested/microcystic features is composed of bland-appearing cells arranged in small infiltrating nests with scattered admixed microcysts. Urothelial carcinoma with plasmacytoid features is morphologically indistinguishable from lobular breast carcinoma; it is typically composed of bland-appearing cells with moderate amphophilic cytoplasm and scattered intracytoplasmic

variants of conventional urothelial carcinoma constitute the vast majority of such tumors, other less common urinary bladder neoplasms, including primary adenocarcinoma, Müllerian-type carcinoma, and villous adenoma, also may show glandular features. Importantly, depending on the location of the tumor within the urinary bladder (ie, dome, anterior wall), these primary urinary bladder tumors may occasionally enter the differential diagnosis of glandular tumors of the urachus. Thus, for surgical pathologists, recognizing the limitations of ancillary tests and potential need for close clinical and radiographic correlation is important for accurate diagnosis and subclassification of urinary bladder tumors with glandular or pseudoglandular features. Indeed, awareness of the morphologic categories and variants of primary urinary bladder neoplasms is important, as prognostic and therapeutic distinctions are now increasingly represented in clinical management guidelines.^{25,26}

Urothelial Carcinoma: Overview

Urothelial carcinoma is the most common primary tumor of the urinary bladder and can demonstrate a remarkable spectrum of morphologic findings.²⁷ While the vast majority of urothelial carcinomas show at least a component of conventional histology, divergent differentiation is common in invasive tumors (up to 30% of cases),^{28,29} and the 2016 World Health Organization (WHO) Classification delineates a number of recognized variants with glandular and/or pseudoglandular features including glandular, micropapillary, nested/microcystic, plasmacytoid/signet ring/diffuse growth pattern, and lipid-rich (lipoid).²⁷ In tumors with distinct or admixed components demonstrating both conventional histology and divergent differentiation, the relative proportion of tumor showing divergent differentiation can range from focal to extensive. Importantly, in invasive tumors with purely divergent differentiation, recognition of a concurrent noninvasive conventional urothelial component or well-established prior history of urothelial carcinoma is critical to appropriate diagnosis.

Urothelial Carcinoma With Glandular Features

Glandular differentiation is present in up to 5% of invasive urothelial carcinomas and may be associated with poor prognosis.^{28–31} Similar to noncystic urachal adenocarcinomas and primary urinary bladder adenocarcinomas, there are generally 3 recognized subtypes of glandular differentiation in invasive urothelial carcinomas: enteric-type, mucinous, and not otherwise specified (Figure 2, A and B; see below for additional details). Enteric-type glandular differentiation is morphologically similar to colorectal adenocarcinoma and typically shows amphophilic to basophilic cytoplasm, prominent acinar and/or cribriform growth, and frequent admixed associated acute inflammation and necrosis (Figure 2, A). Mucinous differentiation is morphologically similar to mucinous adenocarcinomas of other primary sites (ie, lower intestinal tract) and usually shows intestinal-type glandular epithelium embedded within abundant dissecting extracellular mucin; tumor cells show a variety of architectural patterns, including clusters, strips, and/or acini, and may coalesce to form prominent

cribriform structures (Figure 2, B). Signet ring cell-type morphology, composed of discohesive tumor cells with conspicuous intracytoplasmic vacuolization that indents an eccentrically displaced nucleus, may be focal or extensive in tumors with mucinous differentiation but, importantly, in contrast to the plasmacytoid variant of urothelial carcinoma (see below), is always associated with prominent extracellular mucin. Finally, as the name suggests, glandular differentiation not otherwise specified comprises a spectrum of non-enteric-type/nonmucinous glandular morphology. Importantly, while recognition of the diversity of divergent glandular differentiation in urothelial carcinoma is important for accurate subclassification of urinary bladder tumors with glandular features, there is no available compelling evidence to indicate that the specific subtype of glandular differentiation has independent prognostic or therapeutic significance.

Urothelial Carcinoma With Micropapillary Features

The micropapillary variant of urothelial carcinoma is an important type of divergent differentiation for surgical pathologists to recognize, as its presence in mixed or pure forms has increasing clinical implications for patients.³² In contemporary bladder cancer cohorts, the incidence of micropapillary features is less than 5%.^{28,29} Morphologically, the micropapillary variant is similar to micropapillary carcinomas of other primary sites (eg, breast, ovary) and is characterized by the presence of multiple small filiform cell nests without true fibrovascular cores within variably sized lacunae; nuclei are often arranged at the periphery of the cell clusters, and intracytoplasmic vacuolization is common (Figure 2, C).³³ The presence of micropapillary features in invasive urothelial carcinoma is associated with advanced stage at diagnosis and poor response to intravesical therapy,^{34–37} leading some academic groups to support early cystectomy even for patients with non-muscle-invasive disease.^{32,38} Moreover, some studies have reported that increasing proportion of tumor with micropapillary features is associated with decreased disease-specific survival, with essentially any amount associated with an unfavorable prognosis³⁶; however, there is still an ongoing debate regarding whether the presence of micropapillary features is truly a poor prognostic factor independent of pathologic stage.

Urothelial Carcinoma With Nested/Microcystic Features

The nested variant of urothelial carcinoma is another important type of divergent differentiation for surgical pathologists to recognize because, despite its relatively bland cytologic features, its presence in invasive tumors is often associated with high-stage disease.^{39–41} Its incidence in invasive urothelial carcinoma is not well established, however, most studies have found that it is typically present in less than 5% of tumors.²⁹ Morphologically, the nested variant is characterized by infiltrating small solid branching and/or anastomosing nests of mildly atypical cells with minimal stromal response (Figure 2, D); while focal areas of high-grade cytologic atypia may be identified within deeper infiltrative portions of the tumor, the majority of the mass typically appears deceptively bland and may even resemble

←
vacuolization, diffusely infiltrating stroma as single cells and/or solid sheets without extracellular mucin. The lipid-rich (lipoid) variant of urothelial carcinoma is composed of large cells with abundant intracytoplasmic lipid accumulation and scattered pseudolipoblasts showing prominent scalloped nuclear membranes (original magnifications $\times 10$ [A and B] and $\times 20$ [C through F]).

proliferative von Brunn nests in superficial biopsy and transurethral resection specimens.^{39,40,42} Focal tubular differentiation may be present and can appear similar to nephrogenic adenoma.^{40,43} Microcystic features, composed of admixed variably sized cysts lined by bland-appearing urothelial cells with amorphous and/or degenerative cellular intraluminal debris, are relatively uncommon but within the morphologic spectrum of this entity. Indeed, because of these features, the nested/microcystic variant can mimic cystitis cystica (Figure 2, D).⁴⁴ Finally, although the presence of nested/microcystic features in invasive urothelial carcinoma is associated with advanced stage disease at presentation,^{39–41,44} nested/microcystic features do not appear to be a poor prognostic factor independent of pathologic stage.⁴¹

Urothelial Carcinoma With Plasmacytoid/Signet Ring/Diffuse Growth Pattern

Urothelial carcinoma with a plasmacytoid/signet ring/diffuse growth pattern (ie, “the plasmacytoid variant”) is a very important type of divergent differentiation for surgical pathologists to recognize, as its presence in invasive tumors is typically associated with advanced pathologic stage and a very poor overall prognosis.^{45–49} Again, similar to the nested/microcystic variant, the incidence of plasmacytoid features in invasive urothelial carcinoma is not well established, but in general, it is presumed to be present in less than 1% of tumors.^{28,29} Morphologically, the plasmacytoid variant is similar to lobular breast carcinoma and diffuse-type gastric adenocarcinoma and is characterized by low to intermediate nuclear grade tumor cells with eccentrically placed nuclei and abundant eosinophilic cytoplasm (Figure 2, E).⁴⁵ The tumor cells can be strikingly discohesive and form expansile solid or alveolar nests, occasionally invading via a single-file streaking pattern into tissue distant from grossly demonstrable tumor; characteristically, no stromal response (eg, desmoplasia) is evident. Scattered cells with intracytoplasmic vacuoles may give the appearance of signet ring cells; however, as discussed above, true signet ring cell morphology is a feature of mucinous adenocarcinoma, where it is associated with abundant extracellular mucin. Accordingly, the 2016 WHO Classification has regrouped the signet ring variant, previously classified as an adenocarcinoma variant, as a single entity within the plasmacytoid variant of urothelial carcinoma.²⁷ Importantly, the plasmacytoid variant of urothelial carcinoma may present with characteristic intraperitoneal metastases due to a spread along subserosal and fascial planes^{46,47,49}; this predilection for intraperitoneal spread may trigger an intra-abdominal staging evaluation before cystectomy when extensive plasmacytoid/signet ring/diffuse growth pattern is reported in precystectomy urinary bladder biopsies or transurethral resections. It is noteworthy that a small subset of metastatic tumors within the urinary bladder can present with a plasmacytoid/signet ring/diffuse growth pattern (see below). Hence, close clinical, pathologic, and radiographic correlation is always recommended—especially in those cases lacking a conventional (noninvasive or invasive) urothelial carcinoma component.

Urothelial Carcinoma With Lipid-Rich (Lipoid) Features

The lipid-rich (lipoid) variant of urothelial carcinoma is another rare type of divergent differentiation that surgical pathologists may encounter. The incidence of the lipid-rich (lipoid) features in invasive urothelial carcinoma is not well

established, but it is typically presumed to be rare. It is characterized by large atypical cells with prominent lipid-laden intracytoplasmic vacuoles that indent and scallop an eccentrically displaced nucleus (ie, “pseudolipoblasts”; Figure 2, F).^{50,51} Owing to its prominent intracytoplasmic vacuolization, the lipid-rich (lipoid) variant may demonstrate morphologic overlap with other urinary bladder tumors with glandular or pseudoglandular features; however, recognizing the presence of “pseudolipoblasts” and the macrovesicular appearance of the lipid-laden vacuoles is typically sufficient for accurate diagnosis. Although large series of the lipid-rich (lipoid) variant are limited, these tumors may be associated with advanced pathologic stage and a poor prognosis^{50,51}; overall, the clinical significance of such tumors is unclear and needs to be further interrogated in larger cohorts.

Urothelial Carcinoma: Immunohistochemistry

Immunohistochemistry may or may not be helpful in distinguishing variants of urothelial carcinoma from other tumors in the differential diagnosis (see Table 2). In general, conventional urothelial carcinoma shows diffuse CK7 and variable CK20 expression; p63 and GATA3 expression is also characteristic, but tumors may show expression of only 1 (or, in rare cases, neither) of these markers.⁵² It is important to note that for invasive tumors with divergent glandular differentiation, p63 and/or GATA3 may be lost in the glandular component, which may also lose CK7 expression while gaining CK20 and CDX2 expression.^{52–54} Thus, the immunophenotype of urothelial carcinoma with glandular differentiation significantly overlaps that of its main differential diagnoses: noncystic urachal adenocarcinoma, primary urinary bladder adenocarcinoma, and colorectal adenocarcinoma. Importantly, urothelial carcinoma with glandular features is typically negative for nuclear β -catenin accumulation.⁵³ Regardless, in these cases, additional pathologic evaluation and/or clinical and radiographic correlation may be required for definitive diagnosis. Finally, recent data show that, similar to lobular breast carcinoma and diffuse-type gastric adenocarcinoma, the plasmacytoid variant of urothelial carcinoma frequently demonstrates loss of E-cadherin expression by immunohistochemistry.^{55–58} Given the clinical significance of identifying and reporting the plasmacytoid variant of urothelial carcinoma (see above), these data indicate that E-cadherin immunohistochemistry may be a useful ancillary tool for surgical pathologists in routine clinical practice.

Urothelial Carcinoma: Molecular Pathology

Recent advances in the molecular characterization of urothelial carcinoma has facilitated new potential diagnostic, prognostic, and therapeutic strategies. Most notably, *TERT* promoter mutations have been observed in up to 80% of urothelial carcinomas, across histologic types, grades, and stages.^{59–61} Indeed, *TERT* genotypes have been shown to be conserved across spatially, temporally, and morphologically distinct components of a single tumor, further supporting its use as a relatively stable and reliable molecular biomarker.⁶² Although there is evolving evidence as to whether *TERT* promoter mutations portend prognostic significance,^{61,63} *TERT* promoter mutation analysis may be helpful in distinguishing morphologic variants of urothelial carcinoma from benign and malignant mimickers,^{59,64} including primary and metastatic tumors with glandular features.^{22,65,66} In addition, comprehensive next-generation sequencing has

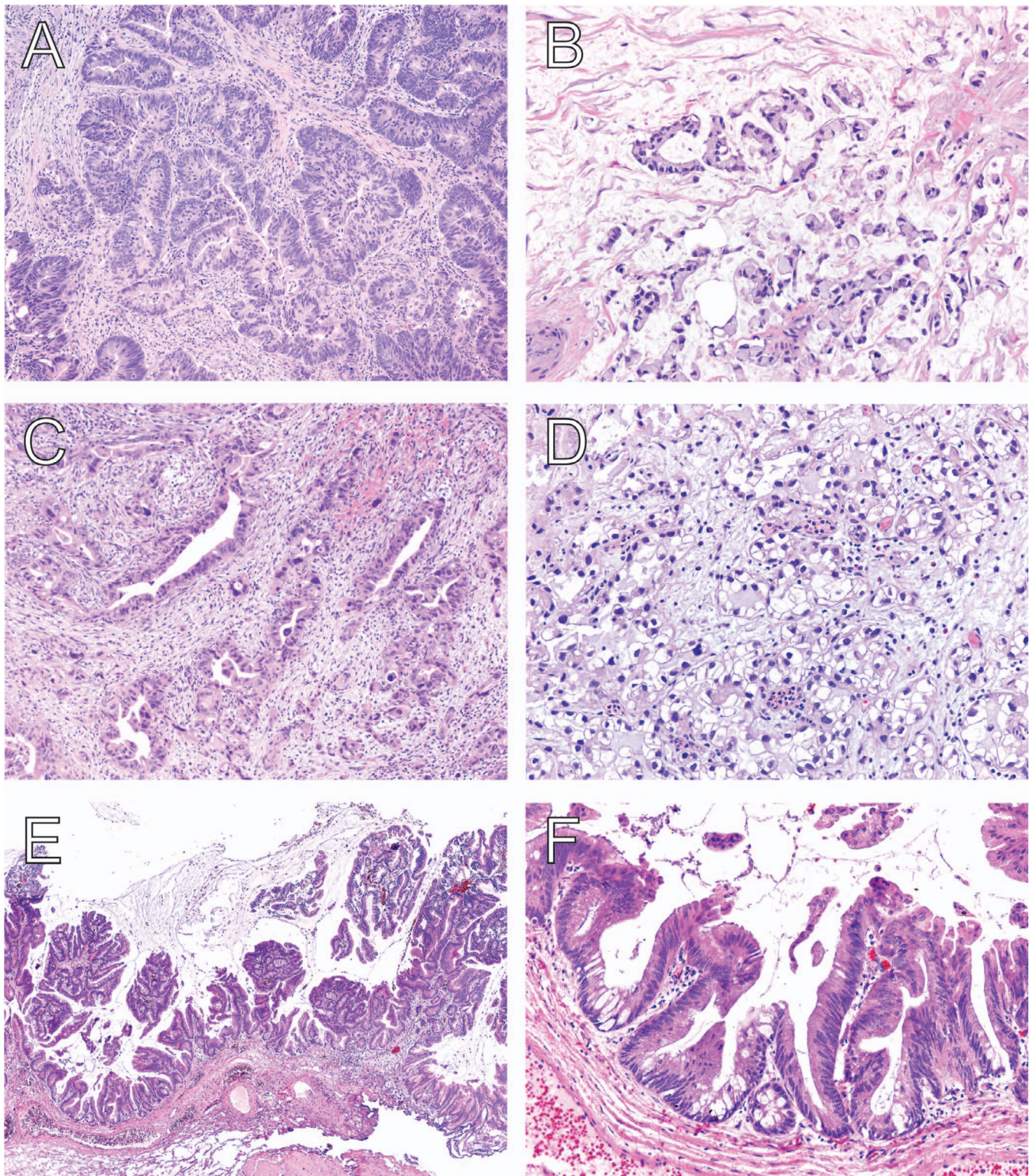


Figure 3. Primary glandular tumors of the urinary bladder. Hematoxylin-eosin (H&E) images showing the morphologic spectrum of primary urinary bladder adenocarcinoma, including (A) enteric; (B) mucinous; and (C) not otherwise specified; all 3 histologic subtypes show morphologic overlap with adenocarcinomas of other primary sites—most notably, the lower intestinal tract (ie, colon, rectum). Müllerian-type carcinomas, such as clear cell carcinoma (D), may uncommonly present as primary urinary bladder tumors and are morphologically similar to Müllerian carcinomas of the gynecologic tract; as the name implies, clear cell carcinoma is typically composed of cells with abundant clear cytoplasm and conspicuous cytologic atypia, arranged in variably sized infiltrating nests with prominent cystic and/or papillary features. E and F, Villous adenoma is an uncommon primary tumor of the urinary bladder, which is morphologically indistinguishable from villous adenomas of the lower intestinal tract (H&E, original magnifications $\times 4$ [E], $\times 10$ [A, C, and F], and $\times 20$ [B and D]).

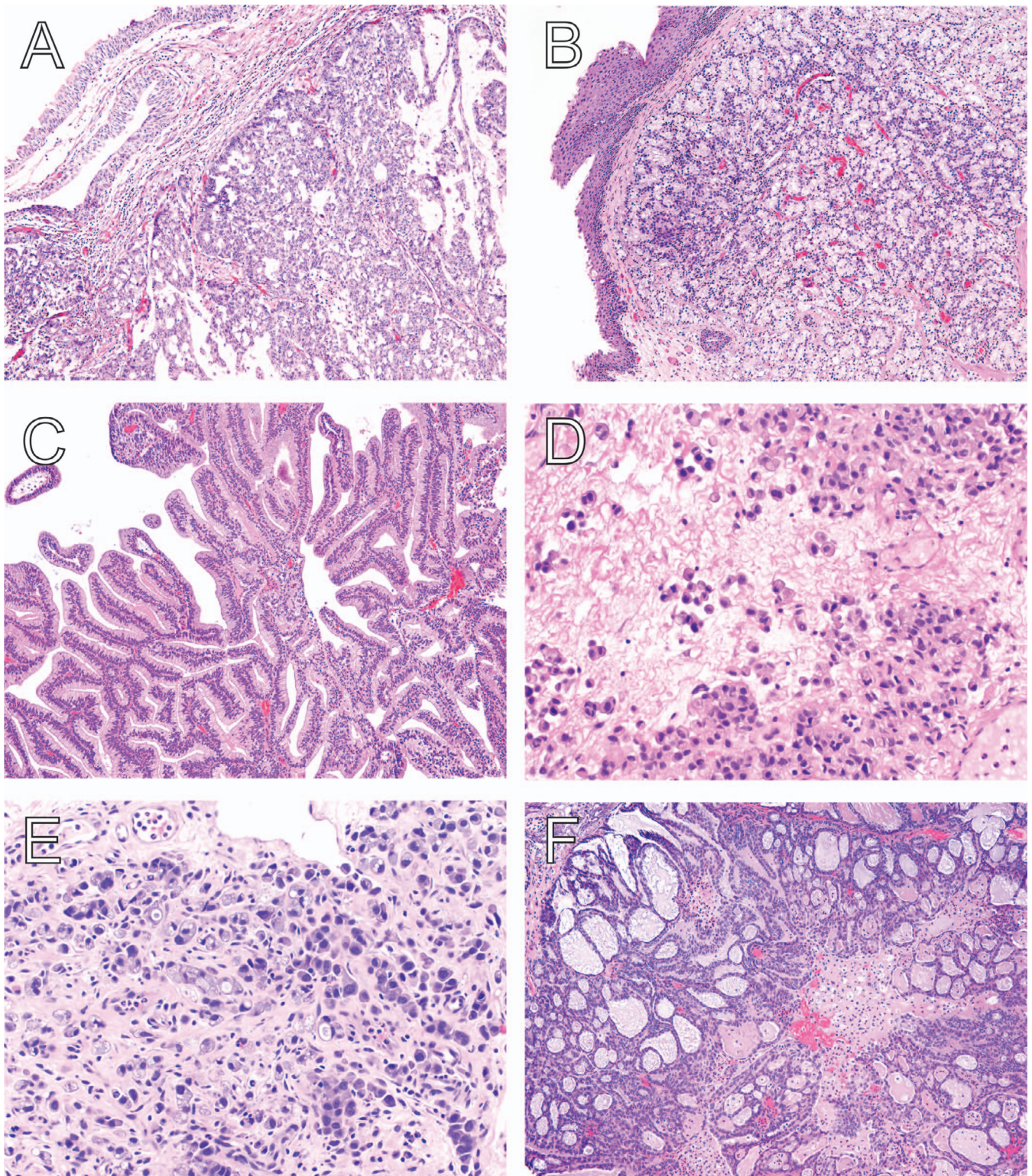


Figure 4. Glandular tumors secondarily involving the urachus or urinary bladder. Hematoxylin-eosin images showing the morphologic spectrum of glandular tumors that may secondarily involve the urachus or urinary bladder, including (A) colorectal adenocarcinoma; (B) prostatic acinar adenocarcinoma; (C) prostatic ductal adenocarcinoma; (D) metastatic lobular breast carcinoma; (E) metastatic diffuse-type gastric adenocarcinoma; and (F) metastatic endometrioid carcinoma. Colorectal adenocarcinoma may show strikingly morphologic and immunophenotypic overlap with primary noncystic urachal adenocarcinoma, urothelial carcinoma with glandular features, and primary urinary bladder adenocarcinoma; close clinical, pathologic, and radiologic correlation is often required for a definitive diagnosis. Prostatic adenocarcinoma is an important differential consideration in male patients and can typically be excluded by routine immunohistochemistry. Although metastatic lobular breast carcinoma and diffuse-type gastric adenocarcinoma show significant morphologic overlap with urothelial carcinoma with plasmacytoid features, immunohistochemistry may help distinguish among these possibilities; clinical, pathologic, and radiologic correlation may also be helpful. Metastatic endometrioid carcinoma from a gynecologic primary is morphologically and immunophenotypically indistinguishable from primary Müllerian-type endometrioid carcinoma of the

identified recurrent molecular alterations in urothelial carcinoma, including somatic mutations in *TP53*, *PIK3CA*, and *FGFR3*, focal amplification of *EGFR*, *PPARG*, and *ERBB2*, and loss of *CDKN2A*⁶⁷; furthermore, integrative transcriptomic analysis has led to multiple systems of molecular subtyping with clinically significant prognostic stratification.⁶⁷⁻⁷² A common thread among these molecular subtyping systems is a broad distinction between a more differentiated “luminal” subtype and a more primitive “basal” subtype (similar to molecular subtyping of breast cancer). While the molecular distinction between variant histologic types has not been fully delineated, there are some characteristic molecular alterations with clinical relevance. For example, the micropapillary variant tends to fall in the aforementioned “luminal” molecular subtype,⁷³ and activating *ERBB2* mutations and/or overexpression of *HER2/neu* is common in the micropapillary variant and may be associated with poor clinical outcome.^{74,75} Interestingly, recent data show that the plasmacytoid variant of urothelial carcinomas shows a high frequency of truncating *CDH1* mutations, which corresponds to loss of E-cadherin expression in most cases.⁵⁷ Continued molecular interrogation of urothelial carcinoma and its histologic variants will likely play key roles in ongoing and future clinical trials for prognostic stratification and targeted therapy.

Primary Adenocarcinoma

In contrast to urothelial carcinoma with glandular features, urinary bladder adenocarcinoma is defined as a primary tumor with *exclusive* glandular differentiation and without concurrent or previous noninvasive or invasive conventional urothelial carcinoma; these criteria highlight the limitation of biopsy assessment and need for extensive sampling of resection specimens. Primary adenocarcinoma of the urinary bladder is an uncommon entity that represents up to 2% of all bladder malignancies.^{76,77} Morphologically, these tumors resemble noncystic urachal adenocarcinomas, and the spectrum of histologic subtypes in primary urinary bladder adenocarcinoma includes enteric, mucinous, and not otherwise specified, which are not independently associated with differences in clinical outcome (Figure 3, A through C).⁷⁸ Similar to noncystic urachal adenocarcinomas, primary urinary bladder adenocarcinomas generally show variable CK7 and diffuse CK20 and CDX2 expression, and nuclear β -catenin accumulation may be seen in a small subset of cases.^{53,79,80} As described above, this immunophenotype is relatively nonspecific in regard to other glandular tumors in the differential diagnosis, and thus, close clinical and radiographic correlation is typically required for diagnosis.

In general, primary urinary bladder adenocarcinomas present at advanced pathologic stage, with concurrent lymph node metastases in up to 40% of cases^{78,81}; when adjusted for pathologic stage and histologic grade, however, cancer-specific mortality is similar to conventional urothelial carcinoma.⁸² Recent next-generation sequencing data have begun to shed light on the molecular underpinnings of primary urinary bladder adenocarcinoma. Indeed, these tumors harbor recurrent mutations in *TP53*, *KRAS*, *PIK3CA*, *CTNNB1*, and *APC*, a spectrum of alterations that is more typically observed in colorectal adenocarcinomas than

conventional urothelial carcinoma.⁸³ Interestingly, however, *TERT* promoter mutations are present in up to one-third of primary urinary bladder adenocarcinomas, indicating potentially that a subset of tumors may be more molecularly related to conventional urothelial carcinoma.⁶⁵

Müllerian-Type Carcinoma

The urinary bladder may also rarely be involved by Müllerian-type carcinomas, including clear cell carcinoma and endometrioid carcinoma. Clear cell carcinoma of the urinary bladder has unique clinicopathologic features and should not be confused with the clear cell variant of urothelial carcinoma. Clear cell carcinoma primarily, but not exclusively, affects women and morphologically resembles clear cell carcinoma of the female gynecologic tract.⁸⁴ Tumors are composed of cells with abundant optically clear cytoplasm and moderate to severe nuclear pleomorphism, arranged in solid sheets, papillary structures, and/or tubulocystic formations lined by hobnail cells within hyalinized stroma (Figure 3, D). Similar to clear cell carcinoma, endometrioid carcinoma of the urinary bladder is a rare tumor that resembles endometrioid carcinoma of the female gynecologic tract.^{85,86} Clear cell carcinoma typically expresses CK7 and PAX8 but is negative for CK20 and p63 expression,^{84,87,88} and endometrioid carcinoma commonly shows estrogen and progesterone receptor expression.⁸⁵

Although large studies are lacking, in general, clear cell carcinoma of the urinary bladder is thought to be an aggressive tumor with a poor clinical outcome. Little is known about the clinical behavior and overall prognosis of endometrioid carcinoma, but the vast majority of cases have been reported in the setting of endometriosis or müllerianosis.^{85,86} Given the clear female sex predominance of these tumors, and coupled with the fact that clear cell carcinoma and endometrioid carcinoma are the 2 most common subtypes of endometriosis-associated malignancy,⁸⁹ it is possible that most Müllerian-type carcinomas of the urinary bladder may arise from preexisting endometriosis or müllerianosis; however, the precise etiology and pathogenesis of such tumors remain unclear, and a subset of Müllerian-type carcinomas may arise through different pathogenetic mechanisms. Regardless, in female patients, particular care should be taken to exclude the possibility of involvement by a prior or concurrent gynecologic tract primary, which often necessitate close clinical, pathologic, and radiographic correlation. Finally, while the molecular pathology of Müllerian-type carcinoma of the urinary bladder has not been explicitly explored, a recent sequencing-based case report of a urethral clear cell carcinoma demonstrated a *ANKRD28-FNDC3B* gene fusion and focal copy loss of *ARID2* and *SMAD4*.⁹⁰

Villous Adenoma

Villous adenoma is an uncommon benign neoplasm of the urinary bladder that nonetheless may be associated with concurrent or subsequent invasive adenocarcinoma in approximately one-third of cases, necessitating diagnostic caution and thorough sampling of available tissue.^{91,92} These tumors are morphologically indistinguishable from villous adenomas of the lower intestinal tract and are typically

← urinary bladder; close clinical, pathologic, and radiologic correlation is required for a definitive diagnosis, particularly in female patients (original magnifications $\times 10$ [A through C, and F] and $\times 20$ [D and E]).

composed of pseudostratified columnar epithelium with variable intracytoplasmic apical mucin and prominent villoglandular architecture (Figure 3, E and F). Similar to their lower intestinal tract counterparts, villous adenomas of the urinary bladder typically show variable CK7 and diffuse CK20 expression.⁹¹ For patients with isolated villous adenoma, recurrence is rare after complete tumor resection; however, patients with concurrent or subsequent invasive adenocarcinoma may develop metastatic disease and have a poor clinical outcome.^{91,92} Finally, it is important to note that primary urachal tumors (including both mucinous cystic tumors and noncystic adenocarcinomas) may have a villous adenoma-like component that projects into the urinary bladder,¹⁴ and thus, for isolated villous adenoma-like tumors in the urinary bladder dome or anterior wall, close clinical and radiographic correlation is recommended to exclude the possibility of unsampled tumor within a urachal remnant.

GLANDULAR TUMORS SECONDARILY INVOLVING THE URACHUS AND/OR URINARY BLADDER

Tumors with pure glandular morphology may secondarily involve the urachus and/or urinary bladder via direct extension or metastasis. It can be especially difficult to distinguish these tumors from primary tumors with glandular features given limitations in specimen (ie, small biopsy specimens) or available clinical history. Secondary tumors account for approximately 2% of cystectomy specimens, of which about 70% are direct extension and 30% are metastases⁹³; while colon, prostate, and cervix are the primary considerations, metastases from the lung, breast, stomach, and kidney have been observed and have morphologic overlap with the primary glandular tumors described above.

Given the significant morphologic and immunophenotypic overlap between colorectal adenocarcinoma and a number of primary urachal or urinary bladder tumors with glandular features, including mucinous cystic urachal tumors, noncystic urachal adenocarcinomas, urothelial carcinoma with glandular features, and primary urinary bladder adenocarcinoma, direct extension or metastasis from a lower intestinal tract primary needs to be in the differential diagnosis of these tumors (Figure 4, A). As described above, recognition of a concurrent conventional urothelial component (either invasive or noninvasive) or elucidation of a prior history of urothelial carcinoma would be most consistent with a diagnosis of urothelial carcinoma with glandular features, while strong and diffuse nuclear β -catenin accumulation would suggest the possibility of involvement by a colorectal adenocarcinoma. Regardless, close clinical and radiographic correlation is required, and in the absence of available clinical and/or radiographic information, earnest attempts should be made to contact the patient's treating clinician, with a specific and detailed comment regarding the differential diagnosis included in the final diagnostic report. In addition, at our institution, we often include the following sentence for clarification: "We would accept this tumor as primary to this site if direct extension and/or metastasis from a [nonurachal/nonurinary bladder] primary can be excluded on clinical and/or radiographic grounds."

Interestingly, while nearly one-quarter of primary urinary bladder tumors arise from the bladder neck and/or trigone, this is the site of up to half of secondary tumors.^{93,94} In men,

direct extension of prostatic adenocarcinoma should be a top differential consideration in urinary bladder tumors with exclusive glandular differentiation. Indeed, in an interesting recent study on prostate cancer mimicking urinary bladder tumors, approximately 3% of newly diagnosed prostate cancers were initially assumed to be primary urinary bladder cancer, and all of these tumors involved the urinary bladder neck, trigone, or both.⁹⁵ Prostatic acinar adenocarcinoma (Figure 4, B) and ductal adenocarcinoma (Figure 4, C), the 2 main subtypes of prostatic adenocarcinoma, are morphologically diverse and can mimic primary adenocarcinoma of the urinary bladder, as well as urothelial carcinoma with glandular features. In these cases, however, immunohistochemistry is typically very helpful, as prostatic adenocarcinomas express NKX3-1 and are typically negative for p63 and GATA3 expression.⁹⁶ Finally, a number of metastatic tumors with glandular or pseudoglandular features may secondarily involve the urinary bladder, including lobular breast carcinoma (Figure 4, D), diffuse-type gastric adenocarcinoma (Figure 4, E), and endometrioid carcinoma (Figure 4, F). In addition to judicious use of immunohistochemistry, in these cases, awareness of the patient's clinical history is paramount.

CONCLUSIONS

Surgical pathologists need to be aware of the broad differential diagnosis of glandular tumors of the urachus and urinary bladder and should tread carefully in small biopsy specimens or when clinical information is not available. In particular, the morphologic overlap between a variety of primary and secondary tumors with glandular or pseudoglandular features can lead to misdiagnosis with significant prognostic and therapeutic implications. In the case of tumors with pure glandular morphology, metastasis and direct extension must be excluded, and in men specifically, prostatic adenocarcinoma should be a consideration for urinary bladder neck and trigone lesions. In summary, accurate diagnosis of glandular tumors of the urachus and urinary bladder requires close clinical and radiographic correlation, as the use of ancillary studies may not be helpful.

The authors would like to thank L. Priya Kunju, MD, of the Department of Pathology at the University of Michigan Medical School for providing hematoxylin-eosin slides from her teaching files for use in generating figures for this manuscript.

References

1. Begg C. The urachus: its anatomy, histology and development. *J Anat*. 1930;(64):170–183.
2. Schubert GE, Pavkovic MB, Bethke-Bedürftig BA. Tubular urachal remnants in adult bladders. *J Urol*. 1982;127(1):40–42.
3. Sheldon CA, Clayman RV, Gonzalez R, Williams RD, Fraley EE. Malignant urachal lesions. *J Urol*. 1984;131(1):1–8.
4. Wright JL, Porter MP, Li CI, Lange PH, Lin DW. Differences in survival among patients with urachal and nonurachal adenocarcinomas of the bladder. *Cancer*. 2006;107(4):721–728.
5. Mostofi FK, Thomson RV, Dean AL. Mucous adenocarcinoma of the urinary bladder. *Cancer*. 1955;8(4):741–758.
6. Gopalan A, Sharp DS, Fine SW, et al. Urachal carcinoma: a clinicopathologic analysis of 24 cases with outcome correlation. *Am J Surg Pathol*. 2009;33(5):659–668.
7. Molina JR, Quevedo JF, Furth AF, Richardson RL, Zincke H, Burch PA. Predictors of survival from urachal cancer: a Mayo clinic study of 49 cases. *Cancer*. 2007;110(11):2434–2440.
8. Dhillon J, Liang Y, Kamat AM, et al. Urachal carcinoma: a pathologic and clinical study of 46 cases. *Hum Pathol*. 2015;46(12):1808–1814.
9. Loening SA, Jacobo E, Hawtrey CE, Culp DA. Adenocarcinoma of the urachus. *J Urol*. 1978;119(1):68–71.
10. Kakizoe T, Matsumoto K, Andoh M, Nishio Y, Kishi K. Adenocarcinoma of urachus: report of 7 cases and review of literature. *Urology*. 1983;21(4):360–366.

11. Johnson DE, Hodge GB, Abdul-Karim FW, Ayala AG. Urachal carcinoma. *Urology*. 1985;26(3):218–221.
12. Gill HS, Dhillon HK, Woodhouse CR. Adenocarcinoma of the urinary bladder. *Br J Urol*. 1989;64(2):138–142.
13. Ashley RA, Inman BA, Sebo TJ, et al. Urachal carcinoma: clinicopathologic features and long-term outcomes of an aggressive malignancy. *Cancer*. 2006;107(4):712–720.
14. Amin MB, Smith SC, Eble JN, et al. Glandular neoplasms of the urachus. *Am J Surg Pathol*. 2014;38(8):1.
15. Paner GP, McKenney JK, Barkan GA, et al. Immunohistochemical analysis in a morphologic spectrum of urachal epithelial neoplasms: diagnostic implications and pitfalls. *Am J Surg Pathol*. 2011;35(6):787–798.
16. Herr HW, Bochner BH, Sharp D, Dalbagni G, Reuter VE. Urachal carcinoma: contemporary surgical outcomes. *J Urol*. 2007;178(1):74–78.
17. Bruins HM, Visser O, Ploeg M, Hulsbergen-van de Kaa CA, Kiemeny LALM, Witjes JA. The clinical epidemiology of urachal carcinoma: results of a large, population based study. *J Urol*. 2012;188(4):1102–1107.
18. Pinthus JH, Haddad R, Trachtenberg J, et al. Population based survival data on urachal tumors. *J Urol*. 2006;175(6):2042–2047.
19. Módos O, Reis H, Niedworok C, et al. Mutations of KRAS, NRAS, BRAF, EGFR, and PIK3CA genes in urachal carcinoma – occurrence and prognostic significance. *Oncotarget*. 2016;7(26):39293–39301.
20. Sirintrapun SJ, Ward M, Woo J, Cimic A. High-stage urachal adenocarcinoma can be associated with microsatellite instability and KRAS mutations. *Hum Pathol*. 2014;45(2):327–330.
21. Collazo-Lorduy A, Castillo-Martin M, Wang L, et al. Urachal carcinoma shares genomic alterations with colorectal carcinoma and may respond to epidermal growth factor inhibition. *Eur Urol*. 2016;70(5):771–775.
22. Thiem S, Herold T, Krafft U, et al. Telomerase reverse transcriptase (TERT) promoter mutations are rare in urachal cancer. *Pathol Int*. 2017;67(12):597–601.
23. Lee S, Lee J, Sim SH, et al. Comprehensive somatic genome alterations of urachal carcinoma. *J Med Genet*. 2017;54(8):572–578.
24. Singh H, Liu Y, Xiao X, et al. Whole exome sequencing of urachal adenocarcinoma reveals recurrent NF1 mutations. *Oncotarget*. 2016;7(20):29211–29215.
25. Chang SS, Bochner BH, Chou R, et al. Treatment of non-metastatic muscle-invasive bladder cancer: AUA/ASCO/ASTRO/SUO Guideline. *J Urol*. 2017;198(3):552–559.
26. Babjuk M, Böhle A, Burger M, et al. EAU Guidelines on Non-Muscle-invasive Urothelial Carcinoma of the Bladder: update 2016. *Eur Urol*. 2016;71(3):447–461.
27. Moch H, Humphrey PA, Ulbright TA, Reuter VE, eds. *WHO Classification of Tumours of the Urinary System and Male Genital Organs*. 4th ed. Lyon, France: IARC; 2016. *World Health Organization Classification of Tumours*; vol 8.
28. Wasco MJ, Daignault S, Zhang Y, et al. Urothelial carcinoma with divergent histologic differentiation (mixed histologic features) predicts the presence of locally advanced bladder cancer when detected at transurethral resection. *Urology*. 2007;70(1):69–74.
29. Shah RB, Montgomery JS, Montie JE, Kunju LP. Variant (divergent) histologic differentiation in urothelial carcinoma is under-recognized in community practice: impact of mandatory central pathology review at a large referral hospital. *Urol Oncol*. 2013;31(8):1650–1655.
30. Lopez-Beltran A, Cheng L. Histologic variants of urothelial carcinoma: differential diagnosis and clinical implications. *Hum Pathol*. 2006;37(11):1371–1388.
31. Lim M, Adsay NV, Grignon D, Osunkoya AO. Urothelial carcinoma with villoglandular differentiation: a study of 14 cases. *Mod Pathol*. 2009;22(10):1280–1286.
32. Kamat AM, Gee JR, Dinney CPN, et al. The case for early cystectomy in the treatment of nonmuscle invasive micropapillary bladder carcinoma. *J Urol*. 2006;175(3):881–885.
33. Amin MB, Ro JY, El-Sharkawy T, et al. Micropapillary variant of transitional cell carcinoma of the urinary bladder: histologic pattern resembling ovarian papillary serous carcinoma. *Am J Surg Pathol*. 1994;18(12):1224–1232.
34. Kamat AM, Dinney CPN, Gee JR, et al. Micropapillary bladder cancer: a review of the University of Texas M. D. Anderson Cancer Center experience with 100 consecutive patients. *Cancer*. 2007;110(1):62–67.
35. Gofrit ON, Yutkin V, Shapiro A, et al. The response of variant histology bladder cancer to intravesical immunotherapy compared to conventional cancer. *Front Oncol*. 2016;6:43.
36. Compérat E, Roupert M, Yaxley J, et al. Micropapillary urothelial carcinoma of the urinary bladder: a clinicopathological analysis of 72 cases. *Pathology*. 2010;42(7):650–654.
37. Samaratunga H, Khoo K. Micropapillary variant of urothelial carcinoma of the urinary bladder: a clinicopathological and immunohistochemical study. *Histopathology*. 2004;45(1):55–64.
38. Willis DL, Fernandez MI, Dickstein RJ, et al. Clinical outcomes of cT1 micropapillary bladder cancer. *J Urol*. 2015;193(4):1129–1134.
39. Wasco MJ, Daignault S, Bradley D, Shah RB. Nested variant of urothelial carcinoma: a clinicopathologic and immunohistochemical study of 30 pure and mixed cases. *Hum Pathol*. 2010;41(2):163–171.
40. Beltran AL, Cheng L, Montironi R, et al. Clinicopathological characteristics and outcome of nested carcinoma of the urinary bladder. *Virchows Arch*. 2014;465(2):199–205.
41. Linder BJ, Frank I, Cheville JC, et al. Outcomes following radical cystectomy for nested variant of urothelial carcinoma: a matched cohort analysis. *J Urol*. 2013;189(5):1670–1675.
42. Volmar KE, Chan TY, De Marzo AM, Epstein JI. Florid von Brunn nests mimicking urothelial carcinoma: a morphologic and immunohistochemical comparison to the nested variant of urothelial carcinoma. *Am J Surg Pathol*. 2003;27(9):1243–1252.
43. Kunju LP. Nephrogenic adenoma: report of a case and review of morphologic mimics. *Arch Pathol Lab Med*. 2010;134(10):1455–1459.
44. Lopez Beltran A, Montironi R, Cheng L. Microcystic urothelial carcinoma: morphology, immunohistochemistry and clinical behaviour. *Histopathology*. 2014;64(6):872–879.
45. Lopez-Beltran A, Requena MJ, Montironi R, Blanca A, Cheng L. Plasmacytoid urothelial carcinoma of the bladder. *Hum Pathol*. 2009;40(7):1023–1028.
46. Kaimakliotis HZ, Monn MF, Cheng L, et al. Plasmacytoid bladder cancer: variant histology with aggressive behavior and a new mode of invasion along fascial planes. *Urology*. 2014;83(5):1112–1116.
47. Ricardo-Gonzalez RR, Nguyen M, Gokden N, Sangoi AR, Presti JC, McKenney JK. Plasmacytoid carcinoma of the bladder: a urothelial carcinoma variant with a predilection for intraperitoneal spread. *J Urol*. 2012;187(3):852–855.
48. Keck B, Wach S, Stoehr R, et al. Plasmacytoid variant of bladder cancer defines patients with poor prognosis if treated with cystectomy and adjuvant cisplatin-based chemotherapy. *BMC Cancer*. 2013;13:71.
49. Dayyani F, Czerniak BA, Sircar K, et al. Plasmacytoid urothelial carcinoma, a chemosensitive cancer with poor prognosis, and peritoneal carcinomatosis. *J Urol*. 2013;189(5):1656–1660.
50. Lopez-Beltran A, Amin MB, Oliveira PS, et al. Urothelial carcinoma of the bladder, lipid cell variant: clinicopathologic findings and LOH analysis. *Am J Surg Pathol*. 2010;34(3):371–376.
51. Leroy X, Gonzalez S, Zini L, Aubert S. Lipoid-cell variant of urothelial carcinoma: a clinicopathologic and immunohistochemical study of five cases. *Am J Surg Pathol*. 2007;31(5):770–773.
52. Paner GP, Annaiah C, Gulmann C, et al. Immunohistochemical evaluation of novel and traditional markers associated with urothelial differentiation in a spectrum of variants of urothelial carcinoma of the urinary bladder. *Hum Pathol*. 2014;45(7):1473–1482.
53. Rao Q, Williamson SR, Lopez-Beltran A, et al. Distinguishing primary adenocarcinoma of the urinary bladder from secondary involvement by colorectal adenocarcinoma: extended immunohistochemical profiles emphasizing novel markers. *Mod Pathol*. 2013;26(5):725–732.
54. Giannico GA, Gown AM, Epstein JI, Revetta F, Bishop JA. Role of SATB2 in distinguishing the site of origin in glandular lesions of the bladder/urinary tract. *Hum Pathol*. 2017;67:152–159.
55. Keck B, Wach S, Kunath F, et al. Nuclear E-cadherin expression is associated with the loss of membranous E-cadherin, plasmacytoid differentiation and reduced overall survival in urothelial carcinoma of the bladder. *Ann Surg Oncol*. 2013;20(7):2440–2445.
56. Fox MD, Xiao L, Zhang M, et al. Plasmacytoid urothelial carcinoma of the urinary bladder. *Am J Clin Pathol*. 2017;147(5):500–506.
57. Al-Ahmadie HA, Iyer G, Lee BH, et al. Frequent somatic CDH1 loss-of-function mutations in plasmacytoid variant bladder cancer. *Nat Genet*. 2016;48(4):356–358.
58. Lim MG, Adsay NV, Grignon DJ, Osunkoya AO. E-cadherin expression in plasmacytoid, signet ring cell and micropapillary variants of urothelial carcinoma: comparison with usual-type high-grade urothelial carcinoma. *Mod Pathol*. 2011;24(2):241–247.
59. Kurtis B, Zhuge J, Ojaimi C, et al. Recurrent TERT promoter mutations in urothelial carcinoma and potential clinical applications. *Ann Diagn Pathol*. 2016;21:7–11.
60. Kinde I, Munari E, Faraj SF, et al. TERT promoter mutations occur early in urothelial neoplasia and are biomarkers of early disease and disease recurrence in urine. *Cancer Res*. 2013;73(24):7162–7167.
61. Allory Y, Beukers W, Sagraera A, et al. Telomerase reverse transcriptase promoter mutations in bladder cancer: high frequency across stages, detection in urine, and lack of association with outcome. *Eur Urol*. 2014;65(2):360–366.
62. Brown NA, Lew M, Weigelin HC, et al. Comparative study of TERT promoter mutation status within spatially, temporally and morphologically distinct components of urothelial carcinoma. *Histopathology*. 2018;72(2):354–356.
63. Rachakonda PS, Hosen I, de Verdier PJ, et al. TERT promoter mutations in bladder cancer affect patient survival and disease recurrence through modification by a common polymorphism. *Proc Natl Acad Sci*. 2013;110(43):17426–17431.
64. Zhong M, Tian W, Zhuge J, et al. Distinguishing nested variants of urothelial carcinoma from benign mimickers by TERT promoter mutation. *Am J Surg Pathol*. 2015;39(1):127–131.
65. Cowan ML, Springer S, Nguyen D, et al. Detection of TERT promoter mutations in primary adenocarcinoma of the urinary bladder. *Hum Pathol*. 2016;53:8–13.
66. Vail E, Zheng X, Zhou M, et al. Telomerase reverse transcriptase promoter mutations in glandular lesions of the urinary bladder. *Ann Diagn Pathol*. 2015;19(5):301–305.

67. The Cancer Genome Atlas Research Network. Comprehensive molecular characterization of urothelial bladder carcinoma. *Nature*. 2014;507(7492):315–322.
68. Hedegaard J, Lamy P, Nordentoft I, et al. Comprehensive transcriptional analysis of early-stage urothelial carcinoma. *Cancer Cell*. 2016;30(1):27–42.
69. Choi W, Porten S, Kim S, et al. Identification of distinct basal and luminal subtypes of muscle-invasive bladder cancer with different sensitivities to frontline chemotherapy. *Cancer Cell*. 2014;25(2):152–165.
70. Damrauer JS, Hoadley KA, Chism DD, et al. Intrinsic subtypes of high-grade bladder cancer reflect the hallmarks of breast cancer biology. *Proc Natl Acad Sci U S A*. 2014;111(8):3110–3115.
71. Seiler R, Ashab HAD, Erho N, et al. Impact of molecular subtypes in muscle-invasive bladder cancer on predicting response and survival after neoadjuvant chemotherapy. *Eur Urol*. 2017;72(4):544–554.
72. Sjobdahl G, Lauss M, Lovgren K, et al. A molecular taxonomy for urothelial carcinoma. *Clin Cancer Res*. 2012;18(12):3377–3386.
73. Guo CC, Dadhania V, Zhang L, et al. Gene expression profile of the clinically aggressive micropapillary variant of bladder cancer. *Eur Urol*. 2016;70(4):611–620.
74. Ross JS, Wang K, Gay LM, et al. A high frequency of activating extracellular domain ERBB2 (HER2) mutation in micropapillary urothelial carcinoma AC. *Clin Cancer Res*. 2014;20(1):68–75.
75. Schneider SA, Sukov WR, Frank I, et al. Outcome of patients with micropapillary urothelial carcinoma following radical cystectomy: ERBB2 (HER2) amplification identifies patients with poor outcome. *Mod Pathol*. 2014;27(5):758–764.
76. Thomas DG, Ward AM, Path MRC, Williams JL. A study of 52 cases of adenocarcinoma of the bladder. *Br J Urol*. 1971;43(1):4–15.
77. Ploeg M, Aben KK, Hulsbergen-van de Kaa CA, Schoenberg MP, Witjes JA, Kiemeny LA. Clinical epidemiology of nonurothelial bladder cancer: analysis of The Netherlands Cancer Registry. *J Urol*. 2010;183(3):915–920.
78. Grignon DJ, Ro JY, Ayala AG, Johnson DE, Ordóñez NG. Primary adenocarcinoma of the urinary bladder: a clinicopathologic analysis of 72 cases. *Cancer*. 1991;67(8):2165–2172.
79. Roy S, Smith MA, Cieply KM, Acquafondata MB, Parwani A V. Primary bladder adenocarcinoma versus metastatic colorectal adenocarcinoma: a persisting diagnostic challenge. *Diagn Pathol*. 2012;7(1).
80. Wang HL, Lu DW, Yerian LM, et al. Immunohistochemical distinction between primary adenocarcinoma of the bladder and secondary colorectal adenocarcinoma. *Am J Surg Pathol*. 2001;25(11):1380–1387.
81. el-Mekresh MM, el-Baz MA, Abol-Enein H, Ghoneim MA. Primary adenocarcinoma of the urinary bladder: a report of 185 cases. *Br J Urol*. 1998;82(2):206–212.
82. Lughezzani G, Sun M, Jeldres C, et al. Adenocarcinoma versus urothelial carcinoma of the urinary bladder: comparison between pathologic stage at radical cystectomy and cancer-specific mortality. *Urology*. 2010;75(2):376–381.
83. Roy S, Pradhan D, Ernst WL, et al. Next-generation sequencing-based molecular characterization of primary urinary bladder adenocarcinoma. *Mod Pathol*. 2017;30(8):1133–1143.
84. Oliva E, Amin MB, Jimenez R, Young RH. Clear cell carcinoma of the urinary bladder: a report and comparison of four tumors of mullerian origin and nine of probable urothelial origin with discussion of histogenesis and diagnostic problems. *Am J Surg Pathol*. 2002;26(2):190–197.
85. Allen D, O'Brien T, Pingle P, Chandra A. Endometrioid adenocarcinoma of the bladder. *Histopathology*. 2005;46(2):232–233.
86. Garavan F, Grainger R, Jeffers M. Endometrioid carcinoma of the urinary bladder complicating vesical Mullerianosis: a case report and review of the literature. *Virchows Arch*. 2004;444(6):587–589.
87. Gilcrease MZ, Delgado R, Vuitch F, Albores-Saavedra J. Clear cell adenocarcinoma and nephrogenic adenoma of the urethra and urinary bladder: a histopathologic and immunohistochemical comparison. *Hum Pathol*. 1998;29(12):1451–1456.
88. Tong GX, Weeden EM, Hamele-Bena D, et al. Expression of PAX8 in nephrogenic adenoma and clear cell adenocarcinoma of the lower urinary tract: evidence of related histogenesis? *Am J Surg Pathol*. 2008;32(9):1380–1387.
89. Kurman RJ, Shih I-M. The dualistic model of ovarian carcinogenesis. *Am J Pathol*. 2016;186(4):733–747.
90. Mehra R, Vats P, Kalyana-Sundaram S, et al. Primary urethral clear-cell adenocarcinoma. *Am J Pathol*. 2014;184(3):584–591.
91. Cheng L, Montironi R, Bostwick DG. Villous adenoma of the urinary tract: a report of 23 cases, including 8 with coexistent adenocarcinoma. *Am J Surg Pathol*. 1999;23(7):764–771.
92. Seibel JL, Prasad S, Weiss RE, Bancila E, Epstein JI. Villous adenoma of the urinary tract: a lesion frequently associated with malignancy. *Hum Pathol*. 2002;33(2):236–241.
93. Bates AW, Baithun SI. Secondary neoplasms of the bladder are histological mimics of nontransitional cell primary tumours: clinicopathological and histological features of 282 cases. *Histopathology*. 2000;36(1):32–40.
94. Stephenson WT, Holmes FF, Noble MJ, Gerald KB. Analysis of bladder carcinoma by subsite. Cystoscopic location may have prognostic value. *Cancer*. 1990;66(7):1630–1635.
95. Liu R, Xie X, Zhang Z, Xu Y. A retrospective study of prostate cancer cases mimicking urothelial cell carcinoma of the bladder. *Eur J Med Res*. 2013;18(1).
96. Oh WJ, Chung AM, Kim JS, et al. Differential immunohistochemical profiles for distinguishing prostate carcinoma and urothelial carcinoma. *J Pathol Transl Med*. 2016;50(5):345–354.