

## Mustelid Herpesvirus-2, a Novel Herpes Infection in Northern Sea Otters (*Enhydra lutris kenyoni*)

Marion Tseng,<sup>1</sup> Michelle Fleetwood,<sup>2</sup> Aimee Reed,<sup>1</sup> Verena A. Gill,<sup>3</sup> R. Keith Harris,<sup>2</sup> Robert B. Moeller,<sup>2</sup> Thomas P. Lipscomb,<sup>2</sup> Jonna A. K. Mazet,<sup>1</sup> and Tracey Goldstein<sup>1,4</sup> <sup>1</sup>Wildlife Health Center, School of Veterinary Medicine, One Shields Avenue, University of California, Davis, California 95616, USA; <sup>2</sup>Armed Forces Institute of Pathology, 6825 16th Street NW, Washington, DC 20306, USA; <sup>3</sup>US Fish and Wildlife Service, Marine Mammals Management, 1011 E Tudor Road, Anchorage, Alaska 99503, USA; <sup>4</sup>Corresponding author (email: tgoldstein@ucdavis.edu)

**ABSTRACT:** Oral ulcerations and plaques with epithelial eosinophilic intranuclear inclusions were observed in northern sea otters (*Enhydra lutris kenyoni*) that died or were admitted for rehabilitation after the 1989 Exxon Valdez oil spill (EVOS) in Alaska, USA. Transmission electron microscopy demonstrated the presence of herpesviral virions. Additionally, a serologic study from 2004 to 2005 found a high prevalence of exposure to a herpesvirus in live-captured otters. Tissues from 29 otters after the EVOS and nasal swabs from 83 live-captured otters in the Kodiak Archipelago were tested for herpesviral DNA. Analysis identified a novel herpesvirus in the gamma subfamily, most closely related to Mustelid herpesvirus-1 from badgers. Results indicated that this herpesvirus is associated with ulcerative lesions but is also commonly found in secretions of healthy northern sea otters.

**Key words:** Alaska, *Enhydra lutris kenyoni*, herpesvirus, northern sea otter, polymerase chain reaction.

The northern sea otter (*Enhydra lutris kenyoni*) in Alaska is a coastal species and ranges from the Aleutian chain to southeast Alaska (Gorbics and Bodkin, 2001). The population in Prince William Sound (PWS) suffered high mortality after the 1989 oil spill when the supertanker Exxon Valdez ran aground. More than 1,000 otters died and more than 300 were treated in rehabilitation centers after the spill (Ballachey et al., 1994).

Evidence of a herpesvirus infection was found in otters treated after oil exposure as oral ulcerative lesions and plaques were seen, and histopathologic examination revealed eosinophilic intranuclear inclusion bodies in the oral mucosal epithelium in and around the grossly observed lesions (Harris et al., 1990). Transmission electron microscopy was performed on specimens

from two animals in rehabilitation, and virions consistent with those of a herpesvirus were detected. Similar oral lesions were also found in biopsies from live animals that were captured near the southern Kenai Peninsula (Harris et al., 1990). Eosinophilic intranuclear inclusions were also identified histopathologically and herpesviral virions ultrastructurally by electron microscopy, in oral, esophageal, and corneal epithelia in a free-ranging sea otter in PWS in 1990 (Reimer and Lipscomb, 1998). Serologic evidence of exposure to a herpesvirus was found in 15% of live-captured otters from the Kodiak Archipelago, Alaska, in 2004 and 2005 (Goldstein et al., 2011). Findings from both studies indicated that a herpesvirus has been circulating in otters in Alaska at least since the late 1980s. Our aims were to molecularly detect and characterize the herpesvirus in tissues collected from sea otters after the Exxon Valdez oil spill (EVOS) and in nasal swabs from live-captured otters in the Kodiak Archipelago and to examine potential demographic factors associated with viral transmission and infection.

Formalin-fixed, paraffin-embedded tissues were archived from 29 northern sea otters that were admitted for rehabilitation after the EVOS in 1989: Biopsies of lesions included ulcers and raised plaques from live otters ( $n=23$ ) and tissues collected at necropsy from those that died ( $n=6$ ). Samples included oral mucosa ( $n=5$ ), lip ( $n=3$ ), tongue ( $n=14$ ), gingiva ( $n=4$ ), esophageal mucosa ( $n=2$ ), and vulva ( $n=1$ ). Histopathologic examination was performed on tissues from all EVOS cases.

In August 2004 and July 2005, free ranging northern sea otters ( $n=83$ ) were captured in the Kodiak Archipelago. Physical examinations were performed on all otters, and nasal swabs were collected and archived for molecular analysis. Animals were classified as pups (0–12 months), juveniles (1–3 yr), or adults ( $\geq 4$  yr) according to methods by Bodkin et al. (2000).

DNA was extracted from nasal swabs and tissue sections (DNeasy Tissue Kit<sup>®</sup> and QIAamp DNA FFPE Tissue Kit<sup>®</sup>, Qiagen Inc, Valencia, California, USA). Degenerate primers were used to amplify a 225–base pair (bp) fragment of a conserved region of the herpesviral DNA polymerase gene (VanDevanter et al., 1996). Parallel polymerase chain reaction (PCR) reactions amplified a 350-bp fragment of the mammalian ferritin gene to control for the PCR amplifiability of the DNA sample. Positive PCR products were cloned and sequenced, and the sequence was compared with known herpesviral sequences in the GenBank Database (National Center for Biotechnology Information, National Library of Medicine, Bethesda, Maryland, USA). Primer sequences were edited out before further analyses, and phylogenetic analysis was performed to compare the newly identified herpesviral fragment with 16 other herpesviral sequences from all three subfamilies. The nucleotide sequences of the DNA polymerase gene fragments were aligned with the use of MUSCLE software (Edgar, 2004). Bayesian analysis of the alignment was performed using Mr. Bayes 3.1 with gamma distributed rate variation (Huelsenbeck and Ronquist, 2001). Four incrementally heated Markov Chains were run for 1,100,000 generations, sampling every 200 generations, where 10% of 1,100,000 iterations were discarded as burn in. The human cytomegalovirus HHV-5 (AF133597) sequence was designated as the outgroup for analysis. Sea otter-specific herpesvirus primers were designed to amplify a 162-bp fragment of the DNA polymerase gene (sense: 5'-CCT

CGG GTA TTC TGC CAT GCT T-3'; antisense: 5'-GCA TAT GGT GCC-AGC TTT AGG G-3') and were used to test all samples for the sea otter herpesviral DNA fragment.

Prevalence of PCR positives in both groups was compared using the chi-square test (Daniel, 2005), and associations with sex and age class were evaluated by chi-square or Fisher's exact test (Fisher, 1935) as appropriate. Agreements between PCR and presence of viral intranuclear inclusion bodies by histopathologic examination of tissues was evaluated by the kappa (K) test (Cohen, 1960). All results were considered statistically significant at  $P \leq 0.05$ , and analyses were performed by using SPSS 17<sup>®</sup> (SPSS Inc, Chicago, Illinois, USA) or Epi Info<sup>®</sup> 2000, version 1.1.2 (Centers for Disease Control and Prevention, Atlanta, Georgia, USA).

Lesions were present in all 29 EVOS cases, and clinical descriptions of the lesions (available for 17/29 cases) included pin-point, bilateral or multiple ulcers (0.2–0.5 cm in diameter) or pale raised plaques on the lingual, gingival, oral, esophageal, and labial mucosa (Fig. 1a). Histologically, plaques were characterized by epithelial hyperplasia and hyperkeratosis, often accompanied by epithelial cell degeneration and ulceration. Eosinophilic intranuclear inclusion bodies were found in the epithelial cells of the lip, tongue, gingiva, oral mucosa, and esophagus in 17 of 29 animals but were not seen in the vulva (Fig. 1b).

Amplifiable DNA was obtained from all but one (vulva) of the 29 EVOS samples, as well as from 62 of the 83 nasal swab samples from the live-captured otters from Kodiak. Sequence analysis of the fragment obtained with the degenerate primers identified a novel fragment of the DNA polymerase gene belonging to the gamma-herpesvirus subfamily (Fig. 2), most closely related to mustelid herpesvirus-1 (MusHV-1, 91%) from European badgers (*Meles meles*). This sequence was also somewhat similar to phocine herpesvirus-2 (PhoHV-2, 69%) and elephantid herpesvirus-4

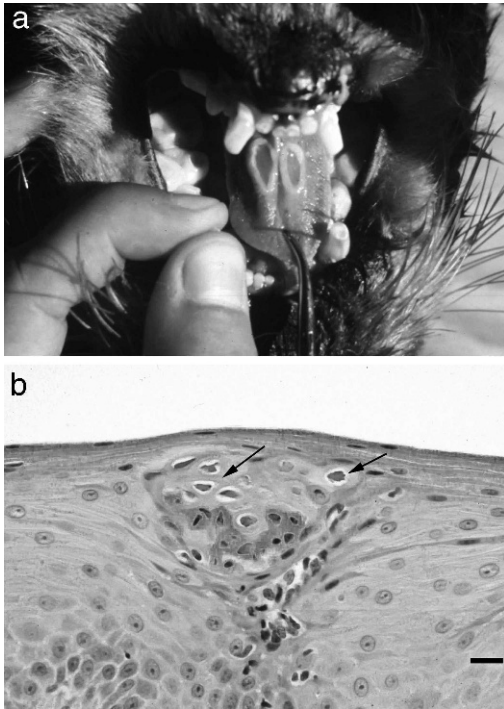


FIGURE 1. Herpesvirus-associated lesions in northern sea otters (*Enhydra lutris kenyoni*) after the 1989 Exxon Valdez oil spill in Alaska, USA. (a) Bilateral lingual ulcers typically seen in sea otters admitted for rehabilitation; (b) photomicrograph showing eosinophilic intranuclear inclusion bodies within a hyperplastic area of a lesion within the oral mucosal epithelium (arrow). H&E stain.

(EIHV-4, 63%). Other related marine mammal gamma herpesviruses were from the Hawaiian monk seal (*Monachus schauinslandi*; PhoHV-3, 63%), northern elephant seal (*Mirounga angustirostris*; PhoHV-4, 61%), California sea lion (*Zalophus californianus*; Otarine HV-1, 57%), Blainville's beaked whale (*Mesoplodon densirostris*; Ziphid HV-1, 63%), bottlenose dolphin (*Tursiops truncatus*; Delphinid HV-4, 62%), and dwarf sperm whale (*Kogia sima*; Kogiid HV-1, 58%).

Positive PCR products were obtained from 46% (13/28) of the EVOS tissues and from 34% (21/62) of the Kodiak nasal swabs (Table 1). The prevalence of PCR positives between the two groups was not statistically different, and neither sex nor age was associated with testing positive.

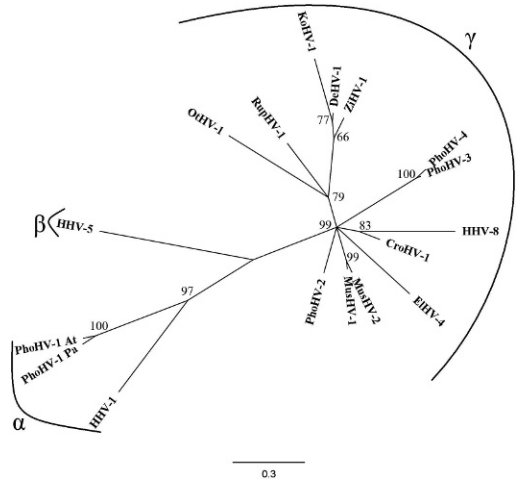


FIGURE 2. Bayesian phylogenetic tree of the nucleotide sequence of the DNA polymerase fragment representing the relationship of the newly identified Mustelid herpesvirus-2 from northern sea otters (*Enhydra lutris kenyoni*; GenBank GU979535) with other herpesviruses. Bayesian posterior probabilities of branchings are shown as percentages at the nodes, herpesviral subfamilies are delineated by brackets. HHV-5 (human cytomegalovirus, AF133597) was used as the outgroup. Sequences of viruses (accession numbers) shown are: MusHV-1 (mustelid herpesvirus-1, badger, AF275657), EIHV-4 (elephantid herpesvirus-4, elephant, DQ238846), RupHV-1 (rupicaprid herpesvirus-1, chamois, DQ-789369), CroHV-1 (crocutid herpesvirus-1, hyena, DQ789371), PhoHV-2 (phocid herpesvirus-2, harbor seal, GQ429152), PhoHV-4 (phocid herpesviruses-4, northern elephant seal, DQ183057), PhoHV-3 (phocid herpesvirus-3, Hawaiian monk seal, DQ093191), OtHV-1 (otariid herpesvirus-1, California sea lion, AF236050), PhoHV-1-Atl (phocid herpesvirus-1, Atlantic harbor seal, Goldstein T., unpubl.), PhoHV-1-Pac (Pacific harbor seal U92269), ZiHV-1 (ziphid herpesvirus-1, Blainville's beaked whale, AY949828), KoHV-1 (kogiid herpesvirus-1, dwarf sperm whale, AY949830), DeHV-1 (delphinid herpesvirus-1, bottlenose dolphin: AY952777), HHV-8 (Kaposi's sarcoma associated, NC003409), HHV-5 (human cytomegalovirus, AF133597), HHV-1 (human herpes simplex-1, X04771).

Kappa analysis indicated poor agreement between PCR and histopathology because results were consistent in 64% of the cases ( $K=0.30$ ; Table 2).

Our data confirm that a novel sea otter herpesvirus in the gammaherpesvirus subfamily was present in and may indicate viral shedding by northern sea otters, in

TABLE 1. Prevalence (number positive/total samples tested) of herpesviral DNA by sex and age class from northern sea otters (*Enhydra lutris kenyoni*) after the Exxon Valdez oil spill in 1989 (tissues) and live captured in the Kodiak Archipelago in 2004 and 2005 (nasal swabs).

	Overall prevalence, %	Sex, %		Age, %		
		Male	Female	Pup	Juvenile	Adult
Tissues	46 (13/28)	57 (4/7)	55 (6/11)	0 (0/2)	100 (1/1)	56 (9/16)
Nasal swabs	34 (21/62)	29 (7/24)	37 (14/38)	100 (2/2)	27 (6/22)	34 (13/38)

that viral nucleic acid was identified in both tissues and nasal swabs. Herpesviruses in the gamma subfamily are predominantly lymphotropic and generally associated with respiratory disease and leukocytosis. Other examples, such as Epstein-Barr virus (HHV-4), causes infectious mononucleosis in humans, and alcephaline herpesvirus-1 causes malignant catarrhal fever in ungulates (Ackermann, 2006). The sea otter herpesvirus is most closely related to MusHV-1 from European badgers. The badger virus was isolated from cell culture and also detected molecularly in European badgers in the British Isles (Banks et al., 2002; King et al., 2004). To date, MusHV-1 has not been associated with lesions or clinical signs. Because herpesviruses are thought to have coevolved with their host species over millions of years (Davison, 2002; McGeoch et al., 2006), it is not surprising that the most closely related herpesvirus to this sea otter virus is from another Mustelid species.

The high prevalence of both herpesviral DNA and characteristic intranuclear inclusion bodies indicated the infection was associated with the ulcerative lesions seen in otters after the EVOS. It is likely that the

high prevalence of lesions was a result of reactivation of the herpesvirus caused by stress from oil exposure, capture, and rehabilitation. Stress-associated reactivation is a characteristic feature of some herpesviral diseases (Roizman 1996). Additionally, otters in close confinement are likely at increased risk for viral transmission. Our findings suggest that this novel virus, Mustelid herpesvirus-2 (MusHV-2), is a common and generally clinically insignificant infection of northern sea otters that could cause disease under conditions of stress and crowding.

Funds for this study were provided by the US Fish and Wildlife Service and the Armed Forces Institute of Pathology and to A.R. through the S.T.A.R. (Students Training in Advanced Research) Program in the School of Veterinary Medicine, University of California, Davis. Live captures were conducted under Division of Management Authority, US Fish and Wildlife Service permits MA041309-2 and MA740507-2. Sincere thanks to personnel from the UC Davis Marine Ecosystem Health Diagnostic and Surveillance Laboratory, US Fish and Wildlife Service, US Geological Survey, Alaska SeaLife Center, and Armed Forces Institute of Pathology.

#### LITERATURE CITED

TABLE 2. Comparison of herpesvirus PCR with the presence of viral intranuclear inclusions by histopathologic examination in tissues from northern sea otters (*Enhydra lutris kenyoni*) after the Exxon Valdez oil spill in Prince William Sound, Alaska, USA.

PCR test	Histopathology, %	
	Positive	Negative
Positive	36 (10/28)	11 (3/28)
Negative	25 (7/28)	29 (8/28)

- ACKERMANN, M. 2006. Pathogenesis of gammaherpesvirus infections. *Veterinary Microbiology* 113: 211–222.
- BALLACHEY, B. E., J. L. BODKIN, AND A. R. DEGANGE. 1994. An overview of sea otter studies. *In* T. R. Loughlin (ed.). *Marine mammals and the Exxon Valdez*. Academic Press, San Diego, California, pp. 47–59.
- BANKS, M., D. P. KING, C. DANIELLS, D. A. STAGG, AND D. GAVIER-WIDEN. 2002. Partial characterization of a novel gammaherpesvirus isolated



- from a European badger (*Meles meles*). *Journal of General Virology* 83: 1325–1330.
- BODKIN, J. L., A. M. BURDIN, AND D. A. RYAZANOV. 2000. Age- and sex- specific mortality and population structure in sea otters. *Marine Mammal Sciences* 16: 201–219.
- COHEN, J. 1960. A coefficient of agreement for nominal scales. *Educational and Psychological Measurement* 20: 37–46.
- DANIEL, W. W. 2005. The chi-square distribution and the analysis of frequencies. *Biostatistics*, 8th Edition. John Wiley & Sons Inc., Hoboken, New Jersey, pp. 593–674.
- DAVISON, A. J. 2002. Evolution of the herpesvirus. *Veterinary Microbiology* 86: 69–88.
- EDGAR, R. 2004. MUSCLE: Multiple sequence alignment with high accuracy and high 389 throughput. *Nucleic Acids Research* 32: 1792–1797.
- FISHER, R. A. 1935. The logic of inductive inference. *Journal of the Royal Statistical Society Series A* 98: 39–54.
- GOLDSTEIN, T., V. A. GILL, P. TUOMI, D. MONSON, A. BURDIN, P. A. CONRAD, J. L. DUNN, C. FIELD, C. JOHNSON, D. A. JESSUP, J. BODKIN, AND A. M. DOROFF. 2011. Assessment of clinical pathology and pathogen exposure in sea otters (*Enhydra lutris*) bordering a threatened population in Alaska. *Journal of Wildlife Diseases* 47: 579–592.
- GORBICS, C. S., AND J. L. BODKIN. 2001. Stock structure of sea otters (*Enhydra lutris kenyoni*) in Alaska. *Marine Mammal Science* 17: 632–637.
- HARRIS, R. K., R. B. MOELLER, T. P. LIPSCOMB, J. M. PLETCHER, R. J. HAEBLER, P. A. TUOMI, C. R. MCCORMICK, A. R. DEGANCE, D. MULCAHY, AND T. D. WILLIAMS. 1990. Identification of a herpes-like virus in sea otters during rehabilitation after the T/V Exxon Valdez oil spill. *In Proceedings of Sea Otter Symposium: Proceedings of a symposium to evaluate the response effort on behalf of sea otters after the T/V Exxon Valdez oil spill into Prince William Sound, Anchorage, Alaska*, K. Bayha and J. Kormendy (eds.). US Fish and Wildlife Service Biology Report 90(12). US Fish and Wildlife Service, Washington, DC, pp. 366–368.
- HUELSENBECK, J. P., AND F. RONQUIST. 2001. Mr Bayes: Bayesian inference of phylogeny. *Bioinformatics* 17: 754–755.
- KING, D. P., N. MUTUKWA, S. LESELLIER, C. CHEESEMAN, M. A. CHAMBERS, AND M. BANKS. 2004. Detection of mustelid herpesvirus-1 infected European badgers (*Meles meles*) in the British Isles. *Journal of Wildlife Diseases* 40: 99–102.
- MCGEOCH, D. J., F. J. RIXON, AND A. J. DAVISON. 2006. Topics in herpesvirus genomics and evolution. *Virus Research* 117: 90–104.
- REIMER, D. C., AND T. P. LIPSCOMB. 1998. Malignant seminoma with metastasis and herpesvirus infection in a free-living sea otter (*Enhydra lutris*). *Journal of Zoo and Wildlife Medicine* 29: 35–39.
- ROIZMAN, B. 1996. Herpesviridae. *In* B. N. Fields, D. M. Knipe and P. M. Howley (eds.). *Field's virology*, 3rd Edition. Lippincott-Raven Publishers, Philadelphia, Pennsylvania, pp. 2221–2229.
- VANDEVANter, D. R., P. WARRENER, L. BENNETT, E. R. SCHULTZ, S. COULTER, R. L. GARBER, AND T. M. ROSE. 1996. Detection and analysis of diverse herpesviral species by consensus primer PCR. *Journal of Clinical Microbiology* 34: 1666–1671.

*Submitted for publication 9 June 2010.*

*Accepted 20 July 2011.*