

## ***Mycoplasma testudineum* in Free-ranging Desert Tortoises, *Gopherus agassizii***

**Elliott R. Jacobson<sup>1,3</sup> and Kristin H. Berry<sup>2</sup>** <sup>1</sup> Department of Small Animal Clinical Sciences, College of Veterinary Medicine, University of Florida, Gainesville, Florida 32610, USA; <sup>2</sup> US Geological Survey, Western Ecological Research Center, Riverside, California 92518, USA; <sup>3</sup> Corresponding author (email: jacobsons@ufl.edu)

**ABSTRACT:** We performed clinico-pathological evaluations of 11 wild Agassiz's desert tortoises (*Gopherus agassizii*) from a translocation project in the central Mojave Desert, California, USA. Group 1 consisted of nine tortoises that were selected primarily due to serologic status, indicating exposure to *Mycoplasma testudineum* (seven) or both *M. agassizii* and *M. testudineum* (two), and secondarily due to clinical signs of upper respiratory tract disease (URTD). Group 2 consisted of two tortoises that were antibody-negative for *Mycoplasma* and had no clinical signs of URTD, but did have other signs of illness. Of the Group 1 tortoises, *M. testudineum*, but not *M. agassizii*, was amplified by polymerase chain reaction and DNA fingerprinted from two tortoises. Using light microscopy, mild to severe pathologic changes were observed in one or more histologic sections of either one or both nasal cavities of each tortoise in Group 1. Our findings support a causal relationship between *M. testudineum* and URTD in desert tortoises.

**Key words:** Desert tortoise, *Gopherus agassizii*, *Mycoplasma agassizii*, *Mycoplasma testudineum*, URTD.

Of pathogens infecting Agassiz's desert tortoise (*Gopherus agassizii*; hereafter desert tortoise [DT] refers to *G. agassizii*, one of two identified species within the desert tortoise species complex [Murphy et al., 2011]), *Mycoplasma agassizii*, a causative agent of upper respiratory tract disease (URTD), is the most well-known from research on pathology, transmission, and antibody prevalence (Brown et al., 2002). A second mycoplasma, *M. testudineum*, has been cultured from a DT with URTD (Brown et al., 2004). In a small transmission study, three gopher tortoises (*Gopherus polyphemus*) inoculated in the nares with *M. testudineum* subsequently developed classic signs of URTD and seroconverted within 8-wk postinoculation (Brown et al., 2004).

Here we present correlative serologic and pathologic findings that support a causal relationship between *M. testudineum* and URTD in wild DTs. Detailed postmortem examinations were performed on seven DTs that only were positive for antibody to *M. testudineum* and on two that had detectable antibody to *M. testudineum* and *M. agassizii*. Two additional DTs, negative for antibodies to *M. testudineum* and *M. agassizii*, served as the outgroup.

In late summer and fall of 2007 and spring of 2008, 408 and 579 DTs, respectively, from a translocation site adjacent to and including the National Training Center, Fort Irwin, San Bernardino County, California, USA (near 116°44'N, 35°08'W), were health assessed in the field using a modification of previously published guidelines (Berry and Christopher, 2001). From 0.5 to 2.0 ml of whole blood was obtained from the subcarapacial vein or brachial plexus of each DT, chilled on ice in the field, centrifuged within 3 hr, and the plasma frozen at -70 C. The frozen plasma was submitted to the University of Florida's (UF) Mycoplasma Laboratory for testing for anti-*M. agassizii* antibodies using an enzyme-linked immunoassay (ELISA; Wendland et al., 2007). The ELISA was modified and also used to detect anti-*M. testudineum* antibodies. A nasal lavage (5–8 ml) was obtained from each DT, chilled in the field, frozen, and submitted to the same laboratory for culture and identification of *Mycoplasma* by polymerase chain reaction (PCR) using species-specific DNA nucleotide sequences (Berish et al., 2010). Restriction fragment length polymorphism analysis of the 16S rRNA gene was conducted on all positive PCR samples to confirm the

identity of the *Mycoplasma* (Brown et al., 2004).

Nine DTs (Group 1) were selected for necropsy primarily based on serologic criteria (ELISA-positive for exposure to *M. testudineum* or *M. agassizii*), and secondarily on clinical signs of URTD (Brown et al, 2002). Group 1 consisted of three females and six males, ranging from young to old adults (Table 1). Clinical signs varied by type, severity, date, and individual DT. Of the nine DTs, five had a nasal discharge and two had wet, moist or damp naris/nares or beak on one or more field evaluations.

Two adult male DTs from the same translocation site served as an outgroup (Group 2) because they lacked signs of URTD and were negative for antibody to *M. agassizii* or *M. testudineum*. One was unable to ambulate and had swollen joints involving all limbs. The second was observed in the field with severe left periocular hemorrhage and subsequently died.

Upon examination at UF, only two Group 1 DTs had a nasal discharge (Fig. 1). The right naris was not patent in one DT (DT3477), and when the rostral head in front of the eyes was longitudinally sectioned, exudate was present in the right nasal cavity (NC). Palpebrae appeared thickened in two DTs. At necropsy, four DTs had normal amounts of fat associated with the pectoral and pelvic girdles, whereas five DTs had mild to moderate serous atrophy of fat. The liver was light brown in all tortoises. For Group 1 DTs the ratio of liver weight to total body weight was 3.16 to 6.94% (Table 1).

At necropsy, one Group 2 DT (DT4590) had evidence of polyarticular and visceral gout. The other Group 2 DT (DT4417) had hemorrhage around the inner margins of the orbit, with subcutaneous hemorrhage extending from the left periorbital area to the base of the cervical subcutaneous connective tissue. Although a specific diagnosis could not be

TABLE 1. Gross weight (Wt), midline carapace length (MCL), liver weight/body weight %, nasal cavity changes, and *Mycoplasma* findings by enzyme-linked immunosorbent assay (ELISA) or polymerase chain reaction (PCR) and DNA fingerprinting (DNAF) for desert tortoises (*Gopherus agassizii*) in the central Mojave Desert, California, USA.

Tortoise no.	Group	Wt (g)	MCL (mm)	Age and sex	Liver wt/Body wt % <sup>a</sup>	Rhinitis <sup>b</sup>	<i>M. agassizii</i> ELISA	<i>M. testudineum</i> ELISA	<i>Mycoplasma</i> PCR/DNAF
3454	1	3,634	273	Old adult male	4.87	LNC-MO, RNC-MO	Negative	Positive	Negative
3468	1	3,575	263	Adult male	6.94	LNC-MO, RNC-MO	Negative	Positive	Negative
3477	1	1,790	221	Adult female	5.14	LNC-SE, RNC-SE	Negative	Positive	Negative
3479	1	1,550	212	Adult female	3.23	LNC-MO, RNC-MI)	Negative	Positive	<i>M. testudineum</i>
3381	1	3,523	262	Adult male	5.56	LNC-SE, RNC-NSL	Negative	Positive	Negative
3408	1	4,805	296	Adult male	3.16	LNC-MO, Right-MI	Positive	Positive	Negative
890	1	4,550	284	Young adult male	4.13	LNC-MO, RNC-NSL	Negative	Positive	Negative
3469	1	1,350	189	Adult female	3.85	LNC-MO, RNC-NSL	Positive	Positive	Negative
3604	1	3,450	268	Adult male	3.25	LNC-MI, RNC-MI	Negative	Positive	<i>M. testudineum</i>
4590	2	2,070	225	Adult male	7.05	NSL	Negative	Negative	Negative
4417	2	3,000	242	Adult male	ND	LNC-NSL, RNC-MI	Negative	Negative	Negative

<sup>a</sup> ND = not determined.

<sup>b</sup> Upper respiratory tract disease (URTD): LNC = left nasal cavity; RNC = right nasal cavity; MI = mild; MO = moderate; SE = severe; NSL = no significant lesion.



FIGURE 1. Nasal discharge in desert tortoise (*Gopherus agassizii*) 3477 from the Central Mojave Desert, California, USA.

made, tissue damage suggested envenomation by a rattlesnake.

Whereas clinical signs are useful indicators of mycoplasmosis in the DT (Schumacher et al., 1997), subclinical mycoplasmosis occurs (Jacobson et al., 1995). Five of the nine Group 1 DTs were seen in the field with either nasal discharge or damp/moist nares on one or more occasions; however, only two had nasal discharge at necropsy. Thus it might be difficult to make an antemortem diagnosis based on clinical signs alone.

Samples of all organs were collected and fixed in 10% neutral buffered formalin, embedded in paraffin, sectioned at 6  $\mu$ m, and stained with hematoxylin and eosin. The NC was removed from other structures of the head and cut in the midline using a rotary tool fitted with a circular stainless steel blade. Following collection of swabs from each cavity and lungs for *Mycoplasma* culture, PCR testing for *Mycoplasma*, and aerobic bacterial culture (see below), each half of the head containing the NC was placed in a decalcification solution (Cal-Ex decalcifier, Fisher Scientific, Fair Lawn, New Jersey, USA) until tissues could be sectioned in a microtome for light microscopy. Minimums of 30 sections were obtained from each NC, with sectioning performed in the dorsal to ventral plane.

The first section and every 10th section were stained.

For light microscopic evaluation of the NC, the following published (Jacobson et al., 1995) criteria were used to classify lesions: 1) Normal: Occasional small subepithelial lymphoid aggregates; rare heterophils in the lamina propria; no changes in the mucosal or glandular epithelium; no edema; 2) Mild Inflammation: Multifocal small subepithelial lymphoid aggregates; multifocally, small numbers of heterophils, lymphocytes, and plasma cells in the lamina propria; mild edema in lamina propria, minimal changes in mucosal epithelium; 3) Moderate Inflammation: Multifocal to focally extensive lymphoid aggregates; diffusely, moderate numbers of heterophils, lymphocytes, and plasma cells in the lamina propria; proliferation and disorganization of the basal epithelium; 4) Severe Inflammation: Focally extensive to diffuse bands of lymphocytes and plasma cells subjacent to and obscuring the overlying mucosal epithelium; large numbers of heterophils in the lamina propria and infiltrating overlying mucosal epithelium; marked edema of the lamina propria; degeneration, necrosis, and loss of the mucosal epithelium with occasional erosion; proliferation of the basal cells of the epithelium with metaplasia (transformation) of the mucous and olfactory epithelium to a basaloid epithelium; occasional squamous metaplasia.

Of the Group 1 DTs, three had no lesions in one or more sections of one NC (Fig. 2), two had mild lesions (Fig. 3) in one or more sections of both NCs, one had moderate lesions in one or more sections of both NCs (Fig. 4), and one had severe lesions (Fig. 5) in one or more sections of both NCs. Three DTs with moderate to severe lesions in the left NC did not have lesions in the right NC. Therefore we recommend examination of both NCs when making a microscopic diagnosis of rhinitis and more than one section from each NC should be examined by light microscopy. One Group 2 DT had mild changes in one




FIGURE 2. Light microscopic image of the normal right nasal cavity olfactory mucosa of desert tortoise (*Gopherus agassizii*) 890. The mucosa is multilayered and comprised of different types of olfactory cells. H&E stain. Bar=50 µm.

NC. This might represent background changes for DTs in this population.

Overall, lesions seen in the NCs of antibody-positive DTs in our study were less diffuse and severe than seen in DTs (Jacobson et al., 1991, 1995) diagnosed with URTD and infected with *M. agassizii*. This could indicate that *M. testudineum* is less pathogenic than *M. agassizii*, or that the DTs we examined were more recently infected and in earlier stages of illness. Experimental studies are needed

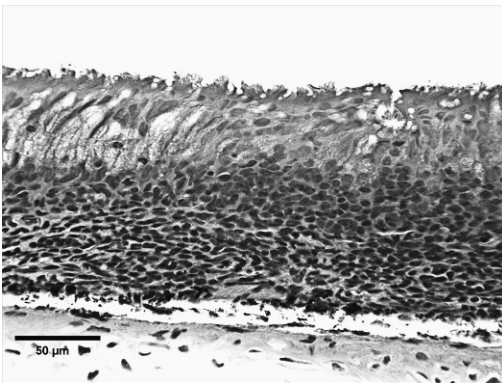


FIGURE 3. Light microscopic image revealing mild lesions in the left nasal cavity olfactory mucosa of desert tortoise (*Gopherus agassizii*) 3468. Subepithelial aggregates of lymphoid cells can be seen. H&E stain. Bar=50 µm.

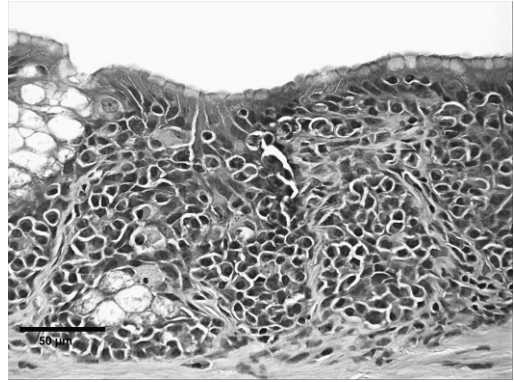


FIGURE 4. Light microscopic image revealing moderate lesions in the right nasal cavity olfactory mucosa of desert tortoise (*Gopherus agassizii*) 3454. Mixed inflammatory cells are seen in the mucosa, with a loss of most mucous epithelial cells. H&E stain. Bar=50 µm.

to better understand the pathogenicity of *M. testudineum* in the DT.

In this study, changes in the palpebrae were often subtle and therefore difficult to categorize. Most DTs were judged, when in the field, to have mild to moderate swelling of the palpebrae in one or both eyes. However, by light microscopy, the palpebrae of three DTs had no significant lesions, three DTs had mild lesions, and

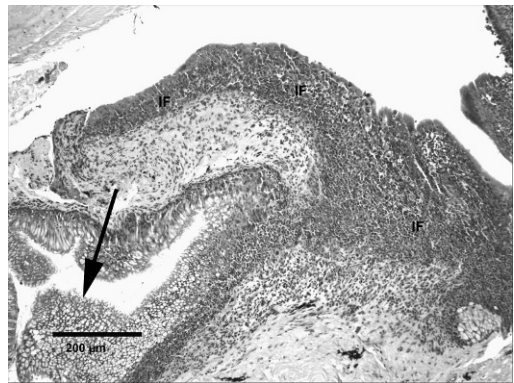


FIGURE 5. Light microscopic image revealing severe lesions in the right nasal cavity mucosa of desert tortoise (*Gopherus agassizii*) 3477. In some areas mixed inflammatory cells (IF) have replaced the mucosa, whereas in other areas there is a hyperplasia of mucous epithelial cells (arrow). The normal cytoarchitecture of the mucosa has been lost. H&E stain. Bar=50 µm.

three DTs had moderate lesions. Mild palpebral changes might represent background changes in wild DTs.

Additional microscopic changes seen in the nine Group 1 DTs included the following: choristoma (adrenal cortical tissue seen in the liver [1]), conjunctivitis (1), cutaneous dyskeratosis (9), glossitis (8), hemosiderosis (8), hepatic lipidosis (9), melanomacrophage hyperplasia (1), and sialadenitis (8). One Group 2 DT had microscopic changes consistent with visceral and polyarticular gout, and the second Group 2 DT had lesions compatible with rattlesnake envenomation.

The following aerobic bacteria were cultured from the nasal cavities of Groups 1 and 2 DTs: *Aerococcus urinae*, *Aerococcus viridans*, *Aeromonas hydrophila*, *Bacillus liceniformis*, *Bacillus pumilus*, *Chromobacterium violaceum*, *Chryseobacterium indologenes*, *Corynebacterium aquaticum*, *Corynebacterium renale*, *Corynebacterium striatum*, *Empedobacter brevis*, *Enterococcus casseliflavus*, *Enterococcus raffinosus*, *Erysepelothrix rhusiopathiae*, *Klebsiella pneumoniae*, *Lactococcus lactis*, *Micrococcus luteus*, *Micrococcus sedentarius*, *Pseudomonas aeruginosa*, *Shewanella putrefaciens*, *Staphylococcus haemolyticus*, *Staphylococcus equorum*, *Staphylococcus sciuri*, *Staphylococcus simulans*, *Streptococcus agalactiae*, and *Streptococcus constellatus*. They probably represent normal bacterial flora of these tissues; none were considered to be a primary pathogen. *Pasteurella testudinis*, an aerobic bacterium first described from DTs with URTD (Snipes and Biberstein, 1982) and isolated from 11 of 19 DTs from Las Vegas Valley with lesions in their NCs (Jacobson et al., 1995), was not isolated from the NCs of tortoises in this study.

Homer et al. (1998) reported that the ratio of liver mass to body weight for DTs with chronic respiratory diseases and urolithiasis ranged from 0.95 to 2.2% of body weight compared to 2.1 to 6.0% for DTs with other diseases. In the current study, the proportion of liver weight to

body weight for Group 1 DTs ranged from 3.16 to 6.94% (Table 1). This included a DT with severe lesions in both NCs consistent with URTD. Possibly, the liver mass to body weight ratio is affected by the chronicity of URTD and other diseases, and the current DTs might have been more recently infected than those described by Homer et al. (1998). All DTs in our study were “well-fed” in late winter and early spring because their forage of wildflowers was common to abundant at that time.

We thank L. Acosta, D. Lyle, K. Lucas, and J. Mack, for field assistance. B. Rideout and J. Simecka provided helpful reviews. The authors also thank A. Childress, D. Hall, S. Forness, L-W. Chang, P. Lewis, and C. Demas for technical assistance; and the Zoological Medicine Service and Veterinary Pathology Service, College of Veterinary Medicine (CVM), University of Florida (UF), Gainesville, Florida, USA, for histopathology support and use of facilities. M. Brown and L. Wendland performed testing for exposure to and infection with *Mycoplasma*. J. Stevens identified aerobic microbes. The Department of the Army, Ft. Irwin, California, USA and the US Geological Survey funded this project. Tortoises were salvaged under permits from the US Fish and Wildlife Service and California Department of Fish and Game to the Department of the Army, Ft. Irwin. This project was approved as UF IACUC Protocol 200801375. Any use of trade names is for descriptive purposes only and does not imply endorsement by the US Government.

#### LITERATURE CITED

- BERISH, J. E., L. D. WENDLAND, R. A. KILTIE, E. P. GARRISON, AND C. A. GATES. 2010. Effects of mycoplasmal upper respiratory tract disease on morbidity and mortality of gopher tortoises in northern and central Florida. *Journal of Wildlife Diseases* 46: 695–705.
- BERRY, K. H., AND M. M. CHRISTOPHER. 2001. Guidelines for the field evaluation of desert

- tortoise health and disease. *Journal of Wildlife Diseases* 37: 427–450.
- BROWN, D. R., I. M. SCHUMACHER, G. S. McLAUGHLIN, L. D. WENDLAND, M. B. BROWN, P. A. KLEIN, AND E. R. JACOBSON. 2002. Application of diagnostic tests for mycoplasmal infections of desert and gopher tortoises, with management recommendations. *Chelonian Conservation and Biology* 42: 497–507.
- , J. L. MERRITT, E. R. JACOBSON, P. A. KLEIN, J. G. TULLY, AND M. B. BROWN. 2004. *Mycoplasma testudineum* sp. nov. from a desert tortoise (*Gopherus agassizii*) with upper respiratory tract disease. *International Journal of Systematic and Evolutionary Microbiology* 54: 1527–1529.
- HOMER, B. L., K. H. BERRY, M. B. BROWN, E. GREINER, AND E. R. JACOBSON. 1998. Pathology of diseases in wild desert tortoises from California. *Journal of Wildlife Diseases* 34: 508–523.
- JACOBSON, E. R., J. M. GASKIN, M. B. BROWN, R. K. HARRIS, C. H. GARDINER, J. L. LAPOINTE, H. P. ADAMS, AND C. REGGIARDO. 1991. Chronic upper respiratory tract disease of free-ranging desert tortoises (*Xerobates agassizii*). *Journal of Wildlife Diseases* 27: 296–316.
- , M. B. BROWN, I. M. SCHUMACHER, B. R. COLLINS, R. K. HARRIS, AND P. A. KLEIN. 1995. Mycoplasmosis and the desert tortoise, *Gopherus agassizii*, in Las Vegas Valley, Nevada. *Chelonian Conservation and Biology* 1: 279–284.
- MURPHY, R. W., K. H. BERRY, T. EDWARDS, A. E. LEVITON, A. LATHROP, AND J. D. RIEDLE. 2011. The dazed and confused identity of Agassiz's land tortoise, *Gopherus agassizii* (Testudines, Testudinidae) with the description of a new species, and its consequences for conservation. *ZooKeys* 113: 39–71.
- SCHUMACHER, I. M., D. B. HARDENBROOK, M. B. BROWN, E. R. JACOBSON, AND P. A. KLEIN. 1997. Relationship between clinical signs of upper respiratory tract disease and antibodies to *Mycoplasma agassizii* in desert tortoises from Nevada. *Journal of Wildlife Diseases* 33: 261–266.
- SNIPES, K. P., AND E. L. BIBERSTEIN. 1982. *Pasteurella testudinis* spp. nov.: A parasite of desert tortoises. *International Journal of Systematic Bacteriology* 32: 201–210.
- WENDLAND, L., L. A. ZACHER, P. A. KLEIN, D. R. BROWN, D. DEMCOVITZ, R. LITTELL, AND M. B. BROWN. 2007. An improved enzyme-linked immunosorbent assay to reveal *Mycoplasma agassizii* exposure: A valuable tool in the management of environmentally sensitive tortoise populations. *Clinical and Vaccine Immunology* 14: 1190–1195.

Submitted for publication 1 September 2011.

Accepted 16 April 2012.