

# Use of a Copper Band to Make Resin Cores in Endodontically Treated Teeth Lacking Coronal Structure

V Alonso de la Peña • IL Darriba • M Caserio Valea  
U Santana-Mora

## Clinical Relevance

We consider the use of a copper band as the most suitable technique for isolating an endodontically treated tooth that has a subgingival margin, while the band also serves as a matrix to fabricate the core.

## SUMMARY

**This article describes the use of a copper band as a matrix to build up resin cores in endodontically treated teeth that have a partially subgingival margin. The copper band is adjusted to the contour of the remaining dental structure and extends beyond the margins to ensure complete isolation in order to provide a matrix to fabricate a core.**

\*Victor Alonso de la Peña, MD, DDS, PhD, Department of Stomatology, Faculty of Medicine and Dentistry, University of Santiago de Compostela, Santiago de Compostela, Spain

Iria L Darriba, Department of Stomatology, Faculty of Medicine and Dentistry, University of Santiago de Compostela, Santiago de Compostela, Spain

Martín Caserio Valea, DDS, Department of Stomatology, Faculty of Medicine and Dentistry, University of Santiago de Compostela, Santiago de Compostela, Spain

Urbano Santana-Mora, Jr, DDS, Department of Stomatology, Faculty of Medicine and Dentistry, University of Santiago de Compostela, Santiago de Compostela, Spain

\*Corresponding author: Entrerrios s/n, 15782, Santiago de Compostela, A Coruña, Spain; e-mail: victorap@mun-do-r.com

DOI: 10.2341/14-206-T

## PURPOSE

It has been suggested that a minimum ferrule of more than 1.5-2 mm is necessary to guarantee the success of restorations for endodontically treated teeth.<sup>1,2</sup> The ferrule length is affected by the biologic width<sup>3</sup> because the maintenance of the biologic width is essential to the health of the supporting tissues.<sup>4</sup> In addition, when one wall of remaining tissue is conserved, there is a reduced risk of failure.<sup>5</sup>

When a fiber-reinforced composite post and a core are required as a result of extensive loss of natural tooth substance, isolation of the operative field must be performed to avoid contamination, especially when using an adhesive technique.<sup>6</sup>

The current authors consider the use of a copper band as the most suitable technique for isolating an endodontically treated tooth that has a subgingival margin, while the band also serves as a matrix to fabricate the core. Copper bands (E. Hahnenkratt GmbH Dentale, Königsbach-Stein, Germany) are available in several diameters, ranging from 5 to 12 mm, and can be hard or soft. The current authors prefer the use of hard copper bands.

The current literature describes the use of a copper band to take impressions,<sup>7</sup> make direct

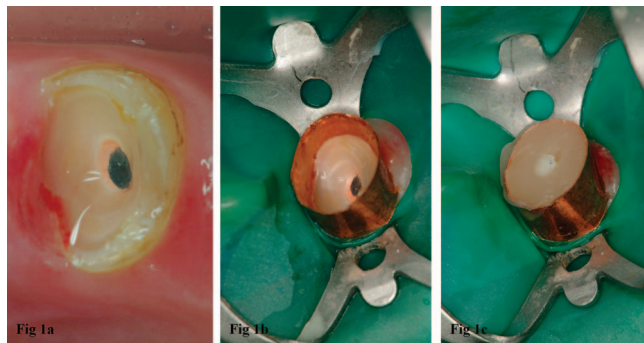


Figure 1. (A) Tooth with a mesial subgingival margin. (B) The copper band allows for the isolation of the operative field with a clamp and rubber dam. (C) Matrix filled with Core•X flow (Dentsply Core & Post System. Dentsply Detrey GmbH, Konstanz, Germany).

restorations,<sup>8</sup> and isolate the operative field in extensively damaged teeth.<sup>9-11</sup>

This current article describes the use of a copper band as a matrix to build up resin cores in endodontically treated teeth with subgingival margins.

### CLINICAL TECHNIQUE

Prior to initiating treatment, it is necessary to evaluate the possibility of restoring a tooth without invading the biologic width.<sup>12</sup> In addition, it is important to take into account whether the prognosis is better if the tooth is restored immediately after endodontic therapy in order to avoid coronal microleakage.<sup>13-16</sup>

In endodontically treated teeth that have subgingival margins, the use of a clamp will impede the correct fit of the matrix on the tooth. In contrast, the use of a copper band, which fits properly below the subgingival area, allows the tooth to be isolated without the need for a rubber dam. Additionally, a clamp can be placed on the tooth after the copper band is placed if a rubber dam is desired to isolate the field (Figure 1).

Prior insertion of the copper band is necessary in order to create a bevel in the infragingival margins and to facilitate the insertion of the copper band.

The selection of the proper diameter of copper band is an important step in this procedure. The copper band should be precisely adjusted to the contour of the remaining dental structure and extend beyond the margins to ensure complete isolation. In those teeth in which the tooth is oval shaped, it is advisable to ensure that the copper band will adapt to the contour of the tooth.

In cases in which there is a remaining wall of dental tissue, the copper band must be cut, following the shape of the margin, to ensure it extends to the subgingival areas. The copper band is then trimmed with curved-tip scissors for cutting metal until its height corresponds to that of the future core, using the height of the adjacent teeth as a guide. The prepared copper band is then seated by applying sufficient vertical pressure. If the operator desires to use thumb pressure, a cotton roll can be interposed between the thumb and the copper band to avoid injury to the thumb. On occasions when more force is required, the patient can be instructed to bite on the cotton roll so that the copper band is seated beyond the margins of the tooth.

In order for the placement of the copper band to be appropriate, it must extend beyond the subgingival margins and be stable. Although insertion of the band can cause gingival bleeding, the blood should not penetrate inside the copper band because the purpose of this technique is to generate an isolated operative field, allowing for the use the adhesive technique to place a post and core under aseptic conditions.

Often, the insertion of the matrix causes some gingival tissue to remain inside the operative area as a result of the cutting effect of the copper band. A dental probe can be used to eliminate this gingival tissue and to confirm the correct placement of the matrix.

Once the tooth is isolated, the post and core are prepared following the manufacturer's recommendations. Once the post and core are fabricated, the copper band is removed by creating a vertical cut along the full height of the copper band with a diamond bur (Figure 2).

Once the post and core are completed, the tooth can be prepared for a crown with margins in healthy dental tissue (Figures 2 and 3),<sup>17</sup> and a temporary crown is placed to assess any changes in the tooth and soft tissues for a few weeks.<sup>18</sup>

### SUMMARY AND ADVANTAGES AND DISADVANTAGES

This technique is useful for restoring endodontically treated teeth when part of their structure is subgingival.

#### Advantages

A copper band is the only matrix that can be shaped intimately to the dental structure in the subgingival area. Copper band isolation allows optimal condi-

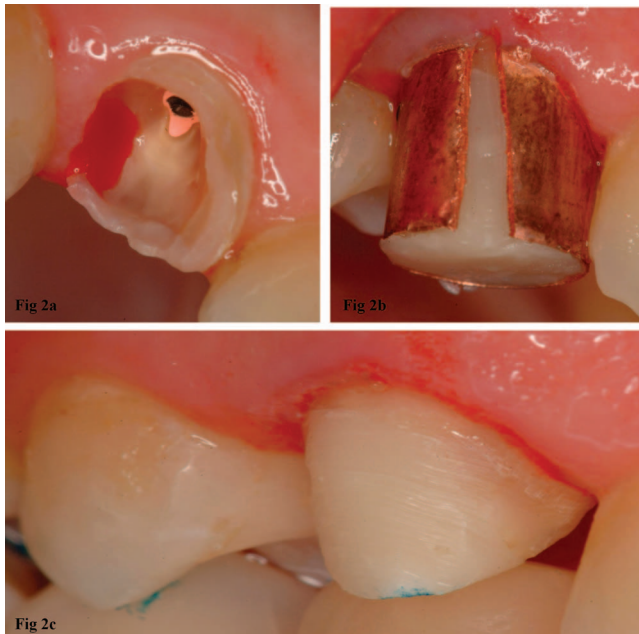


Figure 2. (A) Upper canine with a distal subgingival margin. (B) A vertical cut made in the copper band to enable its removal. (C) The margins of the final preparation in dental tissue.

tions for the adhesive technique, allowing for a direct post and core buildup in teeth with an irregular ferrule.

Unlike other preparations, such as cast-metal post and cores, the use of a copper band does not require removal of healthy dental tissues during preparation.

### Disadvantages

This technique depends on the clinician's skill. It can be difficult to shape the matrix for teeth with irregular forms, such as the interproximal concavities of maxillary premolars, which would require the placement of interproximal wedges.

### Human Subjects Statement

This report was conducted in accordance with all the provisions of the local human subjects oversight committee guidelines and policies of the School of Dentistry Santiago de Compostela, Spain.

### Conflict of Interest

The Authors of this manuscript certify that they have no proprietary, financial or other personal interest of any nature or kind in any product, service and/or company that is presented in this article.

(Accepted 20 January 2015)

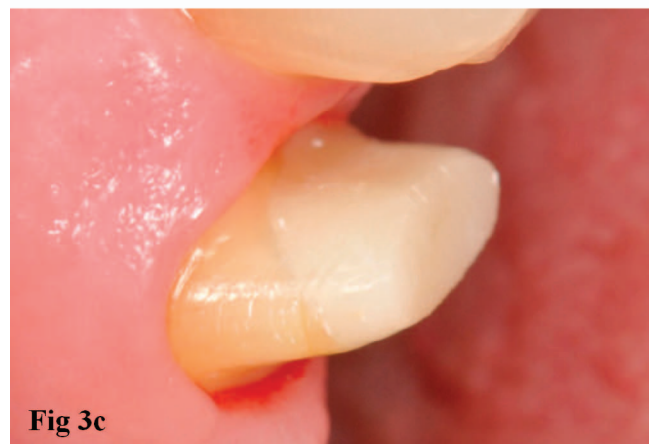
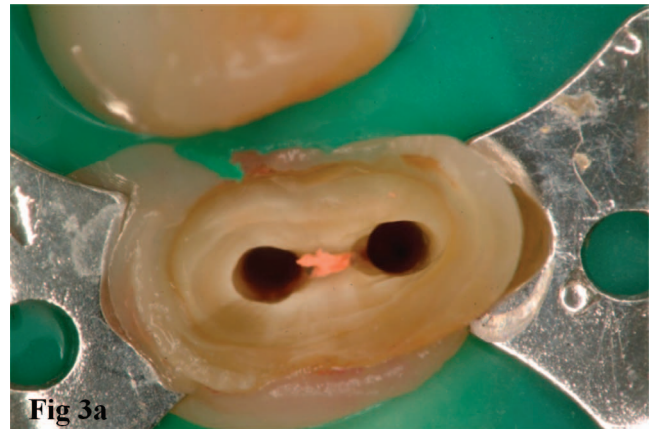

Figure 3. (A) In this case, the post space preparation was performed before placement of the copper band. (B) After placement of the matrix, the posts (Rebilda Post System; VOCO GmbH, Cuxhaven, Germany) were cemented using the adhesive technique. (C) Resin core (Rebilda Post System; VOCO GmbH, Cuxhaven, Germany). The preparation for placement of a crown had margins in healthy tissue.

### REFERENCES

- Schwartz RS, & Robbins JW (2004) Post placement and restoration of endodontically treated teeth: A literature review *Journal of Endodontics* **30**(5) 289-301.

2. Mamoun JS (2014) On the ferrule effect and the biomechanical stability of teeth restored with cores, posts, and crowns *European Journal of Dentistry* **8(2)** 281-286.
3. Juloski J, Radovic I, Goracci C, Vulicevic ZR, & Ferrari M (2012) Ferrule effect: A literature review *Journal of Endodontics* **38(1)** 11-19.
4. de Waal H, & Castellucci G (1993) The importance of restorative margin placement to the biologic width and periodontal health. Part I *International Journal of Periodontics & Restorative Dentistry* **13(5)** 461-471.
5. Ferrari M, Vichi A, Fadda GM, Cagidiaco MC, Tay FR, Breschi L, Polimeni A, & Goracci C (2012) A randomized controlled trial of endodontically treated and restored premolars *Journal of Dental Research* **91(Supplement 7)** 72S-78S.
6. Ree M, & Schwartz RS (2010) The endo-restorative interface: Current concepts *Dental Clinics of North America* **54(2)** 345-374.
7. Small BW (2011) Impression making with gingival hyperplasia using the copper band technique *General Dentistry* **59(5)** 334-337.
8. Feinberg E (2010) Technique for making full-coverage provisional restorations on teeth with insufficient clinical crowns *New York State Dental Journal* **76(6)** 22-26.
9. Smidt A, & Venezia E (2003) Techniques for immediate core buildup of endodontically treated teeth *Quintessence International* **34(4)** 258-268.
10. Linden R (1999) Using a copper band to isolate severely broken teeth before endodontic procedures *Journal of the American Dental Association* **130(7)** 1095.
11. Southard DW (1999) Immediate core buildup of endodontically treated teeth: The rest of the seal *Practical Periodontics and Aesthetic Dentistry* **11(4)** 519-526, quiz 528.
12. Padbury A Jr, Eber R, & Wang HL (2003) Interactions between the gingiva and the margin of restorations *Journal of Clinical Periodontology* **30(5)** 379-385.
13. Alves J, Walton R, & Drake D (1998) Coronal leakage: Endotoxin penetration from mixed bacterial communities through obturated, post-prepared root canals *Journal of Endodontics* **24(9)** 587-591.
14. American Association of Endodontists (2004) Restoration of endodontically treated teeth: The endodontist's perspective, part I; Retrieved online April 12, 2014 from: [http://www.aae.org/uploadedFiles/Publications\\_and\\_Research/Endodontics\\_Colleagues\\_for\\_Excellence\\_Newsletter/ss04ecfeforweb.pdf](http://www.aae.org/uploadedFiles/Publications_and_Research/Endodontics_Colleagues_for_Excellence_Newsletter/ss04ecfeforweb.pdf)
15. Heling I, Gorfil C, Slutzky H, Kopolovic K, Zalkind M, & Slutzky-Goldberg I (2002) Endodontic failure caused by inadequate restorative procedures: Review and treatment recommendations *Journal of Prosthetic Dentistry* **87(6)** 674-678.
16. Faria AC, Rodrigues RC, de Almeida Antunes RP, de MattosMda G, & Ribeiro RF (2011) Endodontically treated teeth: Characteristics and considerations to restore them *Journal of Prosthodontic Research* **55(2)** 69-74.
17. Trushkowsky RD (2014) Restoration of endodontically treated teeth: Criteria and technique considerations *Quintessence International* **45(7)** 557-567.
18. Kosyfaki P, delPilarPinilla Martín M, & Strub JR (2010) Relationship between crowns and the periodontium: A literature update *Quintessence International* **41(2)** 109-126.