

Supplementary Materials

Coronary Angiography in Patients with Left Ventricular Hypertrabeculation/Noncompaction

Nicolas de Cillia, MD¹; Josef Finsterer, MD, PhD²; Radu Campean, MD¹; Ashkan Noorian, MD¹; Maria Winkler-Dworak, PhD³; Claudia Stöllberger, MD¹

¹Klinik Landstrasse, 2nd Medical Department with Cardiology and Intensive Care Medicine, Vienna, Austria

²Klinik Landstrasse, Vienna, Austria

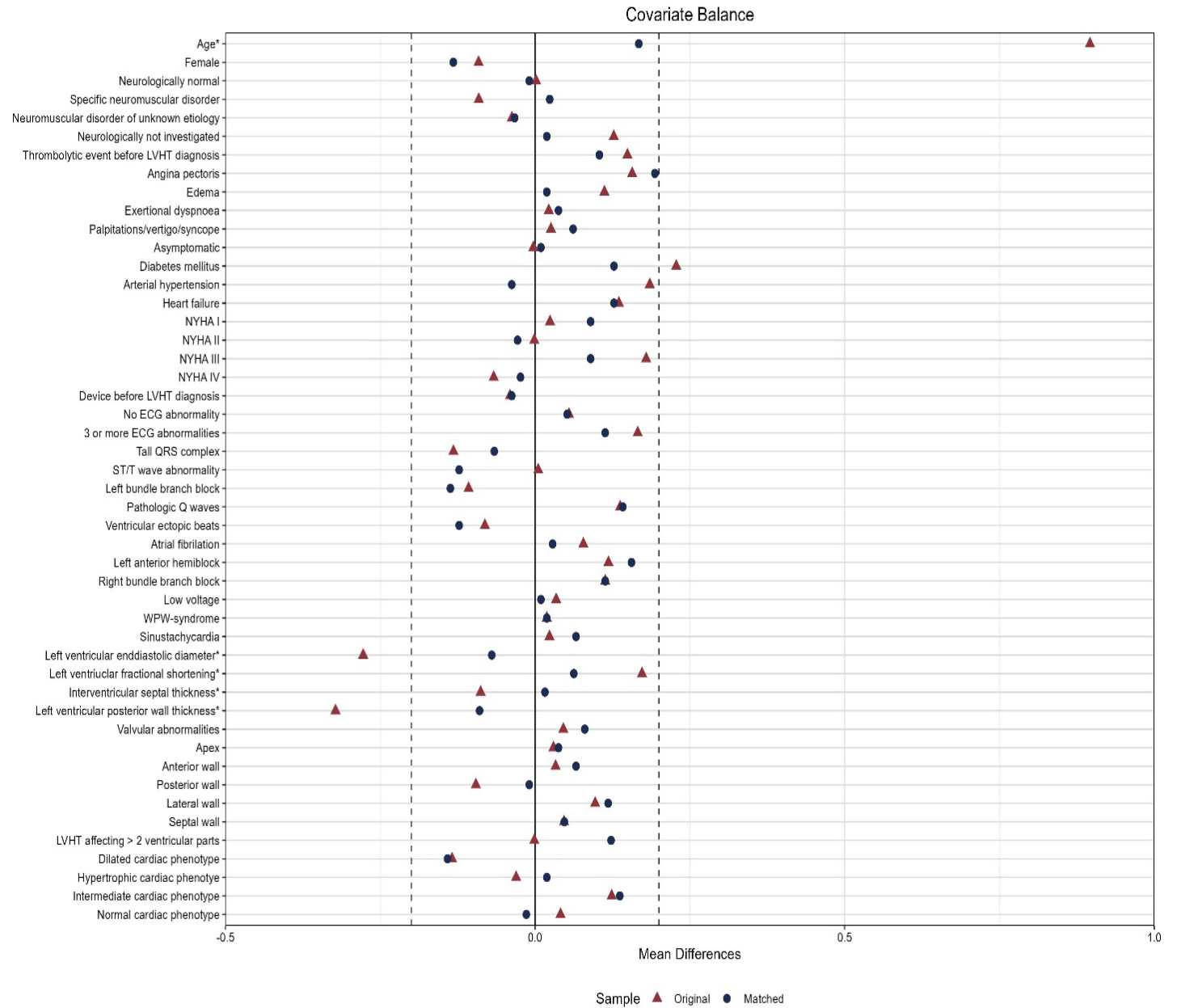
³Vienna Institute of Demography (OeAW), Wittgenstein Centre for Demography and Global Human Capital (IIASA, OeAW, University of Vienna), Vienna, Austria

Citation: *Tex Heart Inst J.* 2024;51(1):e238287. doi: 10.14503/THIJ-23-8287

Corresponding author:

Claudia Stöllberger, MD; Anton-Sattler-Gasse 4/22, A-1220 Wien, Austria
(claudia.stoellberger@chello.at)

Supplemental Figure 1: Plot of the balance according to Mahalanobis matching. All 53 patients with coronary artery disease could be matched to 64 out of 101 patients without coronary artery disease.



* For these variables standardized mean differences are shown.